



## POLICY STATEMENT

# Screening Examination of Premature Infants for Retinopathy of Prematurity

AMERICAN ACADEMY OF PEDIATRICS Section on Ophthalmology, AMERICAN ACADEMY OF OPHTHALMOLOGY, AMERICAN ASSOCIATION FOR PEDIATRIC OPHTHALMOLOGY AND STRABISMUS, and AMERICAN ASSOCIATION OF CERTIFIED ORTHOPTISTS

**KEY WORDS**

retinopathy of prematurity, preterm infants

**ABBREVIATION**

ROP—retinopathy of prematurity

This document is copyrighted and is property of the American Academy of Pediatrics and its Board of Directors. All authors have filed conflict of interest statements with the American Academy of Pediatrics. Any conflicts have been resolved through a process approved by the Board of Directors. The American Academy of Pediatrics has neither solicited nor accepted any commercial involvement in the development of the content of this publication.

All policy statements from the American Academy of Pediatrics automatically expire 5 years after publication unless reaffirmed, revised, or retired at or before that time.

[www.pediatrics.org/cgi/doi/10.1542/peds.2012-2996](http://www.pediatrics.org/cgi/doi/10.1542/peds.2012-2996)

doi:10.1542/peds.2012-2996

PEDIATRICS (ISSN Numbers: Print, 0031-4005; Online, 1098-4275).

Copyright © 2013 by the American Academy of Pediatrics

## abstract

FREE

This statement revises a previous statement on screening of preterm infants for retinopathy of prematurity (ROP) that was published in 2006. ROP is a pathologic process that occurs only in immature retinal tissue and can progress to a tractional retinal detachment, which can result in functional or complete blindness. Use of peripheral retinal ablative therapy by using laser photocoagulation for nearly 2 decades has resulted in a high probability of markedly decreasing the incidence of this poor visual outcome, but the sequential nature of ROP creates a requirement that at-risk preterm infants be examined at proper times and intervals to detect the changes of ROP before they become permanently destructive. This statement presents the attributes on which an effective program for detecting and treating ROP could be based, including the timing of initial examination and subsequent reexamination intervals. *Pediatrics* 2013;131:189–195

## INTRODUCTION

Retinopathy of prematurity (ROP) is a disorder of the developing retina of low birth weight preterm infants that potentially leads to blindness in a small but significant percentage of those infants. In almost all term infants, the retina and retinal vasculature is fully developed, and ROP cannot occur; however, in preterm infants, the development of the retina, which proceeds from the optic nerve head anteriorly during the course of gestation, is incomplete, with the extent of the immaturity of the retina depending mainly on the degree of prematurity at birth.

The Multicenter Trial of Cryotherapy for Retinopathy of Prematurity demonstrated the efficacy of peripheral retinal cryotherapy (ie, cryoablation of the immature, avascular peripheral retina) in reducing unfavorable outcomes for threshold ROP, defined as morphologic changes beyond which the incidence of unfavorable outcome was >50%.<sup>1</sup> The study's 15-year follow-up report<sup>2</sup> confirmed the following lasting benefits: unfavorable structural outcomes were reduced from 48% to 27%, and unfavorable visual outcomes (ie, best corrected visual acuity worse than 20/200) were reduced from 62% to 44%. Subsequently, laser photocoagulation has been used for peripheral retinal ablation with at least equal success and is now the preferred method of ablation.<sup>3–6</sup> More recently, the Early Treatment for Retinopathy of Prematurity Randomized Trial confirmed the efficacy of

treatment of high-risk prethreshold ROP and redefined the indications for treatment.<sup>7</sup>

Because of the sequential nature of ROP progression and the proven benefits of timely treatment in reducing the risk of visual loss, effective care now requires that at-risk infants receive carefully timed retinal examinations by an ophthalmologist who is experienced in the examination of preterm infants for ROP using a binocular indirect ophthalmoscope on a scheduled basis according to their gestational age at birth and their subsequent disease severity and that all pediatricians or any other primary care providers who care for these at-risk preterm infants be aware of this schedule.

This statement outlines the principles on which a program to detect ROP in infants at risk might be based. The goal of an effective ROP screening program is to identify the infants who could benefit from treatment and make appropriate recommendations on the timing of future screening and treatment interventions. Because unchecked ROP can lead to permanent blindness, it is important that all at-risk infants be screened in a timely fashion, recognizing that not all infants require treatment. On the basis of information published thus far, the sponsoring organizations of this statement suggest the following guidelines for the United States. It is important to recognize that other world locations could have different screening parameters.<sup>8,9</sup> It is also important to note that despite appropriate timing of examinations and treatment, a small number of infants at risk progress to poor outcomes.<sup>3-6</sup>

## RECOMMENDATIONS

1. Infants with a birth weight of  $\leq 1500$  g or gestational age of 30 weeks or less (as defined by the attending neonatologist) and se-

lected infants with a birth weight between 1500 and 2000 g or gestational age of  $>30$  weeks with an unstable clinical course, including those requiring cardiorespiratory support and who are believed by their attending pediatrician or neonatologist to be at high risk for ROP, should have retinal screening examinations performed after pupillary dilation by using binocular indirect ophthalmoscopy with a lid speculum and scleral depression (as needed) to detect ROP. Dilating drops should be sufficient to allow adequate examination of the fundi, but care should be used in using multiple drops if the pupil fails to dilate, because poor pupillary dilation can occur in advanced ROP, and administering multiple doses of dilating drops can adversely affect the systemic status of the infant. Sterile instruments should be used to examine each infant to avoid possible cross-contamination of infectious agents. One examination is sufficient only if it unequivocally shows the retina to be fully vascularized in both eyes. Effort may be made to minimize the discomfort and systemic effect of this examination by pretreatment of the eyes with a topical anesthetic agent such as proparacaine; consideration also may be given to the use of pacifiers, oral sucrose, and so forth.

2. Retinal examinations in preterm infants should be performed by an ophthalmologist who has sufficient knowledge and experience to identify accurately the location and sequential retinal changes of ROP. The International Classification of Retinopathy of Prematurity Revisited<sup>10</sup> should be used to classify, diagram, and record these retinal findings at the time of examination.
3. The initiation of acute-phase ROP screening should be based on the

infant's postmenstrual age. The onset of serious ROP correlates better with postmenstrual age (gestational age at birth plus chronologic age) than with postnatal age.<sup>11</sup> That is, the more preterm an infant is at birth, the longer the time to develop serious ROP. This knowledge has been used previously in developing a screening schedule.<sup>12,13</sup> Table 1 was developed from an evidence-based analysis of the Multicenter Trial of Cryotherapy for Retinopathy of Prematurity natural history data and confirmed by the Light Reduction in ROP Study, which was conducted a decade later.<sup>14</sup> It represents a suggested schedule for the timing of the initial eye examinations based on postmenstrual age and chronologic (postnatal) age to detect ROP before it becomes severe enough to result in retinal detachment while minimizing the number of potentially traumatic examinations.<sup>15</sup> Although Table 1 provides a schedule for detecting ROP potentially damaging to the retina with 99% confidence, it should be

**TABLE 1** Timing of First Eye Examination Based on Gestational Age at Birth

Gestational Age at Birth, wk	Age at Initial Examination, wk	
	Postmenstrual	Chronologic
22 <sup>a</sup>	31	9
23 <sup>a</sup>	31	8
24	31	7
25	31	6
26	31	5
27	31	4
28	32	4
29	33	4
30	34	4
Older gestational age, high-risk factors <sup>b</sup>		4

Shown is a schedule for detecting prethreshold ROP with 99% confidence, usually before any required treatment.

<sup>a</sup> This guideline should be considered tentative rather than evidence-based for infants with a gestational age of 22 to 23 wk because of the small number of survivors in these postmenstrual-age categories.

<sup>b</sup> Consider timing based on severity of comorbidities.

appreciated that infants born before 25 weeks' gestational age should be considered for earlier screening on the basis of severity of comorbidities (6 weeks' chronological age, even if before 31 weeks' postmenstrual age to enable earlier identification and treatment of aggressive posterior ROP [a severe form of ROP that is characterized by rapid progression to advanced stages in posterior ROP] that is more likely to occur in this extremely high-risk population).

4. Follow-up examinations should be recommended by the examining ophthalmologist on the basis of retinal findings classified according to the international classification (see Fig 1).<sup>8</sup> The following schedule is suggested:

#### 1-Week or Less Follow-up

- immature vascularization: zone I—no ROP
- immature retina extends into posterior zone II, near the boundary of zone I
- stage 1 or 2 ROP: zone I

- stage 3 ROP: zone II
- the presence or suspected presence of aggressive posterior ROP

#### 1- to 2-Week Follow-up

- immature vascularization; posterior zone II
- stage 2 ROP: zone II
- unequivocally regressing ROP: zone I

#### 2-Week Follow-up

- stage 1 ROP: zone II
- immature vascularization: zone II—no ROP
- unequivocally regressing ROP: zone II

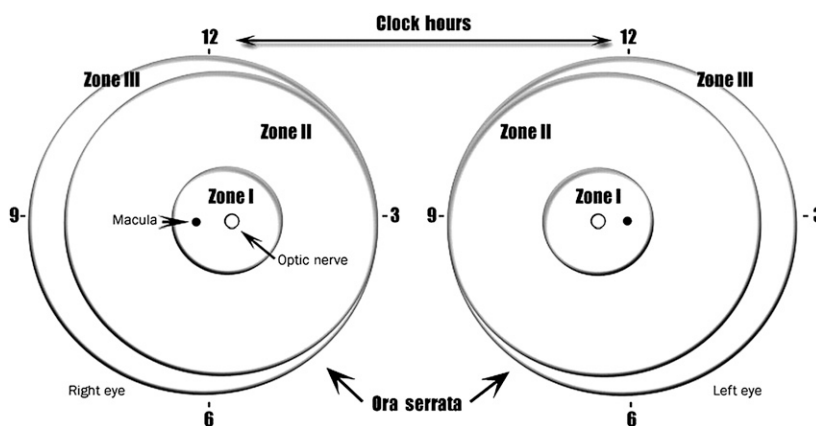
#### 2- to 3-Week Follow-up

- stage 1 or 2 ROP: zone III
- regressing ROP: zone III

5. The conclusion of acute retinal screening examinations should be based on age and retinal ophthalmoscopic findings.<sup>13</sup> Findings that suggest that examinations can be terminated include the following:

- zone III retinal vascularization attained without previous zone I or II ROP (if there is examiner doubt about the zone or if the postmenstrual age is less than 35 weeks, confirmatory examinations may be warranted);
- full retinal vascularization in close proximity to the ora serrata for 360°—that is, the normal distance found in mature retina between the end of vascularization and the ora serrata. This criterion should be used for all cases treated for ROP solely with bevacizumab;
- postmenstrual age of 50 weeks and no prethreshold disease (defined as stage 3 ROP in zone II, any ROP in zone I) or worse ROP is present; or
- regression of ROP<sup>16</sup> (care must be taken to be sure that there is no abnormal vascular tissue present that is capable of reactivation and progression in zone II or III).

6. The use of digital photographic retinal images that are captured and sent for remote interpretation is a developing approach to ROP screening<sup>17,18</sup>; however, outcomes comparison between large-scale operational digital-imaging systems with remote interpretation versus binocular indirect ophthalmoscopy have not been published. Nevertheless, some neonatal centers are conducting remote ROP screening for infants still in the hospital.<sup>17</sup> At a minimum, programs that employ this method should comply with the timing and other recommendations outlined in the preceding guidelines. Protocol modifications may be required to allow for additional time for communication, processing, transportation, or other



**FIGURE 1**

Scheme of retina of the right and left eyes showing zone borders and clock hours used to describe the location and extent of ROP. Diagrammatic representation of the potential total area of the premature retina, with zone I (the most posterior) symmetrically surrounding the optic nerve head (the earliest to develop). A larger retinal area is present temporally (laterally) rather than nasally (medially) (zone III). Only zones I and II are present nasally. The retinal changes discussed in recommendation 4 are usually recorded on a diagram such as this one.

logistical issues.<sup>19</sup> Captured images and their interpretation should be incorporated into the permanent medical record. It is also recommended that indirect ophthalmoscopy be performed at least once by a qualified ophthalmologist before treatment or termination of acute phase screening of ROP for infants at risk for ROP.

Digital image capture (taking of photographs) requires skill, experience, practice, a broad understanding of the infant eye, and ideally, a knowledge of the pathophysiology of ROP (zone, stage, and plus). Remote ROP graders should have the same training requirements as bedside examiners and a mentored experience in interpretation of digital images for ROP. Interpretation requires not only expert knowledge about ROP but also understanding of the limitations of interpreting static images and the special care that must be taken to schedule more frequent imaging sessions that may be required because of those limitations. Remote interpreters must provide clinical input on the timing of follow-up imaging sessions and ophthalmoscopic examinations and appropriate methodology, and these findings need to be communicated in a manner that is compliant with rules of the Health Insurance Portability and Accountability Act (HIPAA).

Digital retinal imaging may also be a useful tool for objective documentation of retinal findings and for teaching NICU staff and parents about examination results, even if it is not the primary method used for ROP screening in the NICU.<sup>20</sup>

ROP care that includes off-site photographic interpretation requires close collaboration among neonatologists, imaging staff, and ophthalmologists. As with all ROP screening programs, specific responsibilities of each individual must be carefully delineated in a written protocol in advance so that repeat imaging and/or confirmatory examinations and required treatments can be performed without delay.

### Treatment

7. The presence of plus disease (defined as abnormal dilation and tortuosity of the posterior retinal blood vessels in 2 or more quadrants of the retina meeting or exceeding the degree of abnormality represented in reference photographs<sup>1,8</sup>; see below) in zones I or II suggests that peripheral ablation, rather than observation, is appropriate.<sup>13</sup>

Treatment should be initiated for the following retinal findings:

- zone I ROP: any stage with plus disease
  - zone I ROP: stage 3—no plus disease
  - zone II: stage 2 or 3 with plus disease
8. Practitioners involved in the ophthalmologic care of preterm infants should be aware that the retinal findings that require strong consideration of ablative treatment were revised according to the Early Treatment of Retinopathy of Prematurity Randomized Trial study.<sup>7</sup> This recommendation is based on the findings of improved visual outcomes with earlier treatment recommended by the Final Visual Acuity Results in the Early Treatment of Retinopathy of Prematurity Study.<sup>21</sup> “Threshold ROP,” a term

that refers to specific morphologic features defined in the Multi-center Trial of Cryotherapy for Retinopathy of Prematurity, is no longer the least severe ROP for which intervention should be considered. Threshold ROP, as defined in the Multicenter Trial of Cryotherapy for Retinopathy of Prematurity study, is now included in type 1 ROP.

Certain levels of high-risk prethreshold disease also respond better to ablative treatment than observation. Special care must be used in determining the zone of disease. The revised International Classification of Retinopathy of Prematurity Revisited classification gives specific examples on how to identify zone I and zone II disease by using a 28-diopter lens with binocular indirect ophthalmoscopy. As noted previously, the presence of plus disease rather than the number of clock hours of disease may be the determining factor in recommending ablative treatment. Treatment should generally be accomplished, when possible, within 72 hours of determination of treatable disease to minimize the risk of retinal detachment. Follow-up is recommended in 3 to 7 days after treatment to ensure that there is no need for additional treatment in areas where ablative treatment was not complete.

9. Recently published data<sup>22</sup> indicate that intravitreal bevacizumab monotherapy, as compared with conventional laser therapy, in infants with stage 3+ ROP showed a significant benefit for zone I but not zone II disease. Development of normal-appearing peripheral retinal vessels continued after treatment with intravitreal bevacizumab, but conventional laser therapy led to apparent permanent destruction of the peripheral retina,

although published studies indicate that this apparent destruction was associated with only a modest visual field loss. This trial was too small to assess safety and effects on future development of brain and other tissues. Consideration may be given to treatment of infants with zone I, stage 3+ ROP with intravitreal injection of bevacizumab; however, bevacizumab is not approved by the US Food and Drug Administration for the treatment of ROP. If intravitreal injection of bevacizumab for zone I stage 3+ ROP is contemplated, it is essential that treatment be administered only after obtaining a detailed informed consent, because there remain unanswered questions involving dosage, timing, safety, visual outcomes, and other long-term effects. Infants treated with bevacizumab injection should be monitored weekly after injection by using techniques in accord with these published ROP examination guidelines until retinal vascularization is completed. Because in the BEAT-ROP study,<sup>22</sup> recurrence of ROP after bevacizumab injection tended to occur considerably later than that after conventional laser peripheral retinal ablative treatment ( $16 \pm 4.6$  weeks vs  $6.2 \pm 5.7$  weeks), longer follow-up is required for infants treated with bevacizumab to ensure that ROP requiring treatment does not recur.

10. Communication with parents by members of the care team is very important, as is documentation of those communications. Parents should be aware of ROP examinations and should be informed if their child has ROP, with subsequent updates on ROP progression. The possible consequences of serious ROP should be discussed at the time that a significant risk of poor

visual outcome develops. Documentation of such conversations with parents in the nurse or physician notes is highly recommended, along with the use of standardized parental educational materials.

11. Responsibility for examination and follow-up of infants at risk for ROP must be carefully defined by the staff and consultants of each NICU. Unit-specific criteria with respect to birth weight and gestational age for examination for ROP should be established for each NICU by consultation and agreement between neonatology and ophthalmology services. These criteria should be recorded and should automatically trigger ophthalmologic examinations. If hospital discharge or transfer to another neonatal unit or hospital is contemplated before retinal development into anterior zone III has taken place or if the infant has been treated by ablation for ROP and there is either incomplete regression or incomplete retinal healing, the availability of appropriate follow-up ophthalmologic examination must be ensured, and specific arrangement for that examination must be made before such discharge or transfer occurs. The transferring primary care physician, after communication with the examining ophthalmologist, should have the responsibility for communicating to the infant's new primary care physician what eye examinations are needed and their required timing. The new primary care physician should ascertain the current ocular examination status of the infant by reviewing the record and communicating with the transferring physician so that any necessary examinations by an ophthalmologist with ongoing experience and

expertise in examination of pre-term infants for ROP can be arranged at the appropriate time at the receiving facility or on an outpatient basis if discharge is contemplated before the need for continued examination has ceased, as outlined in Diagnosis Recommendation 6. If responsibility for arranging follow-up ophthalmologic care after discharge is delegated to the parents, they must be made to understand the potential for severe visual loss, including blindness; that there is a critical examination time schedule to be met if treatment is to be successful; and that timely follow-up examination is essential to successful treatment. This information should be communicated both verbally and in writing and should be carefully documented in the infant's medical record. If such arrangements for communication and follow-up after transfer or discharge cannot be made, the infant should not be transferred or discharged until appropriate follow-up examination can be arranged by the unit staff who are discharging the infant.

Regardless of whether infants at risk develop ROP requiring treatment, pediatricians and other physicians who care for infants who have had ROP should be aware that these infants are at risk for other seemingly unrelated visual disorders, such as strabismus, amblyopia, high refractive errors, cataract, and so forth. Ophthalmologic follow-up for these potential problems after discharge from the NICU is indicated within 4 to 6 months after discharge.

This statement replaces the previous statement on ROP from the American Academy of Pediatrics, American Academy of Ophthalmology, and American Association for Pediatric

Ophthalmology and Strabismus<sup>23</sup>; ROP care is evolving, and recommendations may be modified as additional data about ROP risk factors, treatments, and long-term outcomes are published.

#### LEAD AUTHOR

Walter M. Fierson, MD

#### SUBCOMMITTEE ON RETINOPATHY OF PREMATURITY, AMERICAN ACADEMY OF PEDIATRICS, SECTION ON OPHTHALMOLOGY, 2007–2011

Walter M. Fierson, MD, Chairperson  
Richard A. Saunders, MD  
William Good, MD  
Earl A. Palmer, MD  
Dale Phelps, MD

James Reynolds, MD  
Michael F. Chiang, MD

#### EXECUTIVE COMMITTEE, AMERICAN ACADEMY OF PEDIATRICS, SECTION ON OPHTHALMOLOGY, 2011–2012

James B. Ruben, MD, Chairperson  
David B. Granet, MD, Chairperson-Elect  
Richard J. Blocker, MD  
Geoffrey E. Bradford, MD  
Daniel J. Karr, MD  
Gregg T. Lueder, MD, Immediate Past Chairperson  
Sharon S. Lehman, MD  
R. Michael Siatkowski, MD

#### LIAISONS

Kyle A. Arnoldi, CO – *American Association of Certified Orthoptists*

Christie L. Morse, MD – *American Association of Pediatric Ophthalmology and Strabismus*,  
*American Academy of Ophthalmology*  
George S. Ellis Jr, MD – *American Academy of Ophthalmology Council*

#### STAFF

Jennifer G. Riefe, MEd

#### AMERICAN ACADEMY OF OPHTHALMOLOGY

#### AMERICAN ASSOCIATION FOR PEDIATRIC OPHTHALMOLOGY AND STRABISMUS

#### AMERICAN ASSOCIATION OF CERTIFIED ORTHOPTISTS

#### REFERENCES

1. Cryotherapy for Retinopathy of Prematurity Cooperative Group. Multicenter trial of cryotherapy for retinopathy of prematurity. Preliminary results. *Arch Ophthalmol*. 1988; 106(4):471–479
2. Palmer EA, Hardy RJ, Dobson V, et al; Cryotherapy for Retinopathy of Prematurity Cooperative Group. 15-year outcomes following threshold retinopathy of prematurity: final results from the multicenter trial of cryotherapy for retinopathy of prematurity. *Arch Ophthalmol*. 2005;123(3): 311–318
3. McNamara JA, Tasman W, Brown GC, Federman JL. Laser photocoagulation for stage 3+ retinopathy of prematurity. *Ophthalmology*. 1991;98(5):576–580
4. Hunter DG, Repka MX. Diode laser photocoagulation for threshold retinopathy of prematurity. A randomized study. *Ophthalmology*. 1993;100(2):238–244
5. Laser ROP Study Group. Laser therapy for retinopathy of prematurity. *Arch Ophthalmol*. 1994;112(2):154–156
6. Iverson DA, Trese MT, Orgel IK, Williams GA. Laser photocoagulation for threshold retinopathy of prematurity. *Arch Ophthalmol*. 1991;109(10):1342–1343
7. Early Treatment for Retinopathy of Prematurity Cooperative Group. Revised indications for the treatment of retinopathy of prematurity: results of the early treatment for retinopathy of prematurity randomized trial. *Arch Ophthalmol*. 2003;121(12):1684–1694
8. Gilbert C, Fielder A, Gordillo L, et al; International NO-ROP Group. Characteristics of infants with severe retinopathy of prematurity in countries with low, moderate, and high levels of development: implications for screening programs. *Pediatrics*. 2005;115(5). Available at: [www.pediatrics.org/cgi/content/full/115/5/e518](http://www.pediatrics.org/cgi/content/full/115/5/e518)
9. Gilbert C. Retinopathy of prematurity: a global perspective of the epidemics, population of babies at risk and implications for control. *Early Hum Dev*. 2008;84(2):77–82
10. International Committee for the Classification of Retinopathy of Prematurity. The International Classification of Retinopathy of Prematurity revisited. *Arch Ophthalmol*. 2005;123(7):991–999
11. Palmer EA, Flynn JT, Hardy RJ, et al; The Cryotherapy for Retinopathy of Prematurity Cooperative Group. Incidence and early course of retinopathy of prematurity. *Ophthalmology*. 1991;98(11):1628–1640
12. LIGHT-ROP Cooperative Group. The design of the multicenter study of light reduction in retinopathy of prematurity (LIGHT-ROP). *J Pediatr Ophthalmol Strabismus*. 1999;36(5):257–263
13. Hutchinson AK, Saunders RA, O'Neil JW, Lovering A, Wilson ME. Timing of initial screening examinations for retinopathy of prematurity. *Arch Ophthalmol*. 1998;116(5): 608–612
14. Reynolds JD, Hardy RJ, Kennedy KA, Spencer R, van Heuven WA, Fielder AR; Light Reduction in Retinopathy of Prematurity (LIGHT-ROP) Cooperative Group. Lack of efficacy of light reduction in preventing retinopathy of prematurity. *N Engl J Med*. 1998;338(22):1572–1576
15. Reynolds JD, Dobson V, Quinn GE, et al; CRYO-ROP and LIGHT-ROP Cooperative Study Groups. Evidence-based screening criteria for retinopathy of prematurity: natural history data from the CRYO-ROP and LIGHT-ROP studies. *Arch Ophthalmol*. 2002;120(11):1470–1476
16. Repka MX, Palmer EA, Tung B; Cryotherapy for Retinopathy of Prematurity Cooperative Group. Involvement of retinopathy of prematurity. *Arch Ophthalmol*. 2000;118(5):645–649
17. Lorenz B, Spasovska K, Elflein H, Schneider N. Wide-field digital imaging based telemedicine for screening for acute retinopathy of prematurity (ROP). Six-year results of a multicentre field study. *Graefes Arch Clin Exp Ophthalmol*. 2009;247(9):1251–1262
18. Silva RA, Murakami Y, Lad EM, Moshfeghi DM. Stanford University network for diagnosis of retinopathy of prematurity (SUNDRP): 36-month experience with telemedicine screening. *Ophthalmic Surg Lasers Imaging*. 2011;42(1):12–19
19. Chiang MF, Wang L, Busuioic M, et al. Telemedical retinopathy of prematurity diagnosis: accuracy, reliability, and image quality. *Arch Ophthalmol*. 2007;125(11): 1531–1538
20. Scott KE, Kim DY, Wang L, et al. Telemedical diagnosis of retinopathy of prematurity intraphysician agreement between ophthalmoscopic examination and image-based interpretation

- [published online ahead of print May 23, 2008]. *Ophthalmology*. doi:10.1016/j.ophtha.2007.09.006
21. Good WV, Hardy RJ, Dobson V, et al; Early Treatment for Retinopathy of Prematurity Cooperative Group. Final visual acuity results in the early treatment for retinopathy of prematurity study. *Arch Ophthalmol*. 2010;128(6):663–671
  22. Mintz-Hittner HA, Kennedy KA, Chuang AZ; BEAT-ROP Cooperative Group. Efficacy of intravitreal bevacizumab for stage 3+ retinopathy of prematurity. *N Engl J Med*. 2011; 364(7):603–615
  23. Section on Ophthalmology American Academy of Pediatrics; American Academy of Ophthalmology; American Association for Pediatric Ophthalmology and Strabismus. Screening examination of premature infants for retinopathy of prematurity. *Pediatrics*. 2006;117(2):572–576