



Screening Examination of Premature Infants for Retinopathy of Prematurity

Walter M. Fierson, MD, FAAP, AMERICAN ACADEMY OF PEDIATRICS Section on Ophthalmology, AMERICAN ACADEMY OF OPHTHALMOLOGY, AMERICAN ASSOCIATION FOR PEDIATRIC OPHTHALMOLOGY AND STRABISMUS, AMERICAN ASSOCIATION OF CERTIFIED ORTHOPTISTS

This policy statement revises a previous statement on screening of preterm infants for retinopathy of prematurity (ROP) that was published in 2013. ROP is a pathologic process that occurs in immature retinal tissue and can progress to a tractional retinal detachment, which may then result in visual loss or blindness. For more than 3 decades, treatment of severe ROP that markedly decreases the incidence of this poor visual outcome has been available. However, severe, treatment-requiring ROP must be diagnosed in a timely fashion to be treated effectively. The sequential nature of ROP requires that infants who are at-risk and preterm be examined at proper times and intervals to detect the changes of ROP before they become destructive. This statement presents the attributes of an effective program to detect and treat ROP, including the timing of initial and follow-up examinations.

INTRODUCTION

Retinopathy of prematurity (ROP) is a disorder of the developing retinal blood vessels in preterm infants who are low birth weight and is a leading cause of childhood blindness. In almost all term infants, the retina and retinal vasculature are fully developed, and, therefore, ROP cannot occur; however, in preterm infants, the development of the retina, which proceeds peripherally from the optic nerve head during the course of gestation, is incomplete, with the extent of the immaturity of the retina depending mainly on the degree of prematurity at birth, thus creating the possibility for abnormal development.

In the Multicenter Trial of Cryotherapy for Retinopathy of Prematurity, researchers demonstrated the efficacy of peripheral retinal cryotherapy (ie, cryoablation of the immature, avascular peripheral retina) in reducing unfavorable outcomes for threshold ROP, defined as morphologic changes beyond which the incidence of unfavorable outcome was >50%.¹ In the study's 15-year follow-up report,² authors confirmed the following

abstract

FREE

Dr Fierson was responsible for writing and revising the policy statement and responding to reviewers' concerns and has approved the final manuscript as submitted.

This document is copyrighted and is property of the American Academy of Pediatrics and its Board of Directors. All authors have filed conflict of interest statements with the American Academy of Pediatrics. Any conflicts have been resolved through a process approved by the Board of Directors. The American Academy of Pediatrics has neither solicited nor accepted any commercial involvement in the development of the content of this publication.

Policy statements from the American Academy of Pediatrics benefit from expertise and resources of liaisons and internal (AAP) and external reviewers. However, policy statements from the American Academy of Pediatrics may not reflect the views of the liaisons or the organizations or government agencies that they represent.

The guidance in this statement does not indicate an exclusive course of treatment or serve as a standard of medical care. Variations, taking into account individual circumstances, may be appropriate.

All policy statements from the American Academy of Pediatrics automatically expire 5 years after publication unless reaffirmed, revised, or retired at or before that time.

DOI: <https://doi.org/10.1542/peds.2018-3061>

Address correspondence to Walter M. Fierson, MD, FAAP. E-mail: wfierson@yahoo.com

PEDIATRICS (ISSN Numbers: Print, 0031-4005; Online, 1098-4275).

Copyright © 2018 by the American Academy of Pediatrics

To cite: Fierson WM, AAP AMERICAN ACADEMY OF PEDIATRICS Section on Ophthalmology, AAP AMERICAN ACADEMY OF OPHTHALMOLOGY, AAP AMERICAN ASSOCIATION FOR PEDIATRIC OPHTHALMOLOGY AND STRABISMUS, AAP AMERICAN ASSOCIATION OF CERTIFIED ORTHOPTISTS. Screening Examination of Premature Infants for Retinopathy of Prematurity. *Pediatrics*. 2018;142(6):e20183061

lasting benefits: unfavorable structural outcomes were reduced from 48% to 27%, and unfavorable visual outcomes (ie, best corrected visual acuity worse than 20/200) were reduced from 62% to 44%. Subsequently, laser photocoagulation has been used for peripheral retinal ablation with at least equal success and is now the preferred method of ablation.³⁻⁶ More recently, in the Early Treatment of Retinopathy of Prematurity Randomized Trial (ETROP), researchers confirmed the efficacy of treatment of high-risk prethreshold ROP (recategorized as type 1 ROP), redefined the indications for treatment, and replaced the terms “prethreshold ROP” and “threshold ROP” with “type 1 ROP” (aggressive, treatment-requiring) and “type 2 ROP” (more indolent, less aggressive), respectively.⁷

Because of the usually predictable and sequential nature of ROP progression and the proven benefits of timely treatment in reducing the risk of visual loss, efficacious care now requires that infants who are at risk receive carefully timed retinal examinations to identify treatment-requiring ROP in time for that treatment to be effective. These examinations should be performed by an ophthalmologist who is experienced in the examination of preterm infants for ROP using a binocular indirect ophthalmoscope. The examinations should be scheduled according to the preterm infant’s gestational age at birth and subsequent disease presence and severity, with all pediatricians or other primary care providers who care for the at-risk preterm infant aware of this schedule. When implemented properly, telemedicine systems using wide-angle retinal images and clinical data may be used for preliminary ROP screening or as an adjunct to binocular indirect ophthalmoscopy for ROP screening.

This statement outlines the principles on which a program to detect, follow, and treat ROP in infants who are at risk might be based. The goal of an effective ROP screening program is to identify infants who could benefit from treatment and make appropriate recommendations on the timing of future screening and treatment interventions. Because undiagnosed or treatment-delayed ROP can lead to permanent blindness, it is important that all infants who are at risk be screened in a timely fashion, recognizing that not all infants require treatment. On the basis of information published thus far, the sponsoring organizations of this statement suggest the following recommendations for the United States. It is important to recognize that other locations around the world could have different screening parameters.^{8,9} It is also important to note that despite appropriate timing of examinations and treatment, a small number of at-risk infants with ROP still progress to blindness.³⁻⁶

RECOMMENDATIONS

1. All infants with a birth weight of ≤ 1500 g or a gestational age of 30 weeks or less (as defined by the attending neonatologist) and selected infants with a birth weight between 1500 and 2000 g or a gestational age of >30 weeks who are believed by their attending pediatrician or neonatologist to be at risk for ROP (such as infants with hypotension requiring inotropic support, infants who received oxygen supplementation for more than a few days, or infants who received oxygen without saturation monitoring) should be screened for ROP. Retinal screening examinations should be performed after pupillary dilation by using binocular indirect ophthalmoscopy with

a lid speculum and scleral depression (as needed) to detect ROP. Dilating drops should be sufficient to allow adequate examination of the fundi, but care should be taken in using multiple drops if the pupil fails to dilate because poor pupillary dilation can occur in advanced ROP, and administering multiple doses of dilating drops can adversely affect the cardiorespiratory and gastrointestinal status of the infant. Separate sterile instruments or instruments cleaned in accord with the anti-infective protocol for metal instruments for each NICU should be used to examine each infant to avoid possible cross-contamination by infectious agents. One examination is sufficient only if it unequivocally reveals the retina to be fully vascularized in both eyes. Effort should be made to minimize the discomfort and systemic effect of this examination. In recent literature, authors suggest that a carefully organized program of remotely interpreted wide-angle fundus camera ROP screening may initially be used in place of binocular indirect ophthalmoscope examinations up to the point at which treatment of ROP is believed to be indicated; at this point, indirect ophthalmoscopy is required. This possibility is further discussed in recommendation 6.

2. Retinal examinations in preterm infants should be performed by an ophthalmologist who has sufficient knowledge and experience to accurately identify the location and sequential retinal changes of ROP. The International Classification of Retinopathy of Prematurity Revisited (ICROP)¹⁰ should be used to classify, diagram, and record these retinal findings at the time of examination.

The initiation of acute-phase ROP screening should be based on the infant's postmenstrual age because the onset of serious ROP correlates better with postmenstrual age (gestational age at birth plus chronologic age) than with postnatal age.¹¹ That is, the more preterm an infant is at birth, the longer the time to develop serious ROP. This knowledge has been used previously in developing a screening schedule.^{12,13} Table 1 was developed from an evidence-based analysis of the Multicenter Trial of Cryotherapy for Retinopathy of Prematurity natural history data and confirmed by the Light Reduction in ROP Study, which was conducted a decade later.¹⁴ It represents a suggested schedule for the timing of the initial eye examinations based on postmenstrual age and chronologic (postnatal) age to detect ROP before it becomes severe enough to result in retinal detachment while minimizing the number of potentially traumatic examinations.¹⁵ In Table 1, a rigorously tested schedule is provided for detecting treatable ROP with high confidence in infants with gestational ages of 24 to 30 weeks. However, its recommendations are extrapolated for gestational ages of 22 and 23 weeks. Although there is little evidence that initiating earlier screening is beneficial, some practitioners have advocated for earlier screening on the basis of speculation that treatable aggressive posterior retinopathy of prematurity (AP-ROP) (a severe form of ROP that is characterized by rapid progression to advanced stages in posterior ROP) could occur before 31 weeks' postmenstrual age. Because there is no significant body of evidence to support either practice, each practitioner and NICU will have to rely on clinical

TABLE 1 Timing of First Eye Examination Based on Gestational Age at Birth

Gestational Age at Birth, wk	Age at Initial Examination, wk	
	Postmenstrual	Chronologic
22 ^a	31	9
23 ^a	31	8
24	31	7
25	31	6
26	31	5
27	31	4
28	32	4
29	33	4
30	34	4
Older gestational age, high-risk factors ^b	—	4

Shown is a schedule for detecting prethreshold ROP with 99% confidence, usually before any required treatment. —, not applicable.

^a This guideline should be considered tentative rather than evidence based for infants with a gestational age of 22 to 23 wk because of the small number of survivors in these postmenstrual age categories.

^b Consider timing on the basis of the severity of comorbidities.

judgment as to the initiation of screening in preterm infants of 22 and 23 weeks' gestational age.

3. Authors of recent reports of neonatal algorithms, such as WIN-ROP,¹⁶ Co-ROP,¹⁷ and CHOP-ROP,¹⁸ take factors into account other than birth weight, postmenstrual age, or gestational age. These factors include rapid postnatal weight gain and may be helpful in selecting infants at risk for ROP who should be screened and in eliminating some infants from the need for screening despite their meeting the previously mentioned screening criteria. Substitution of these algorithms for the screening measures described in this article is not justified by current literature, and it is not clear that these criteria apply to international populations.
4. Follow-up examinations should be recommended by the examining ophthalmologist on the basis of retinal findings classified according to the "International classification of retinopathy of prematurity revisited" (see Fig 1).⁸ The following schedule is suggested as an acceptable one for most infants, but certain infants may require an altered frequency of examinations, remembering that the goal of examinations is to

offer treatment at the time when it is most likely to succeed.

One-Week-or-Less Follow-up

- Zone I: immature vascularization, no ROP;
- Zone I: stage 1 or stage 2 ROP;
- Immature retina extending into posterior zone II, near the boundary of zone I–zone II;
- Suspected presence of AP-ROP; and
- Stage 3 ROP, zone I requires treatment, not observation.

One- to 2-Week Follow-up

- Posterior zone II: immature vascularization;
- Zone II: stage 2 ROP; and
- Zone I: unequivocally regressing ROP.

Two-Week Follow-up

- Zone II: stage 1 ROP;
- Zone II: no ROP, immature vascularization; and
- Zone II: unequivocally regressing ROP.

Two- to 3-Week Follow-up

- Zone III: stage 1 or 2 ROP; and
- Zone III: regressing ROP.

5. The termination of acute retinal screening examinations should

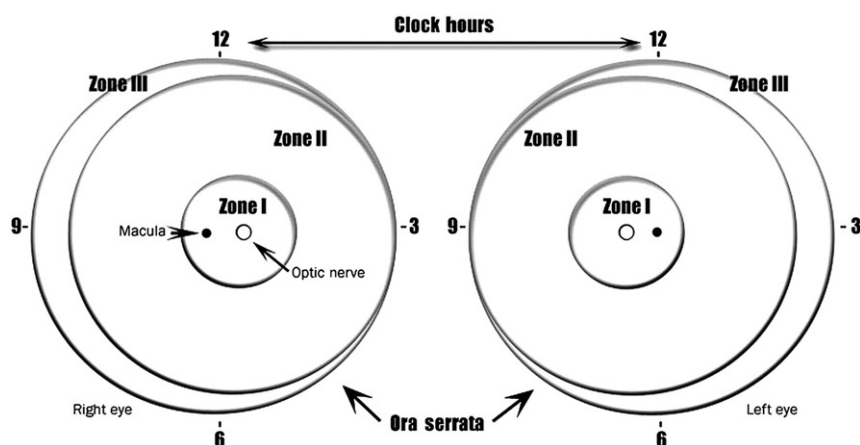


FIGURE 1 Scheme of retina of the right and left eyes showing zone borders and clock hours used to describe the location and extent of ROP. Diagrammatic representation of the potential total area of the premature retina, with zone I (the most posterior) symmetrically surrounding the optic nerve head (the earliest to develop) is shown. A larger retinal area is present temporally (laterally) rather than nasally (medially) (zone III). Only zones I and II are present nasally. The retinal changes discussed in recommendation 4 are usually recorded on a diagram such as this one.

be based on age and retinal ophthalmoscopic findings.¹³ Findings in which it is suggested that examinations can be terminated include the following:

- Full retinal vascularization in close proximity to the ora serrata for 360°, that is, the normal distance found in mature retina between the end of vascularization and the ora serrata. This criterion should also be used for all cases treated for ROP solely with anti-vascular endothelial growth factor (VEGF) injectable medications.
 - Zone III retinal vascularization attained without previous zone I or II ROP (if there is examiner doubt about the zone or if the postmenstrual age is less than 35 weeks, confirmatory examinations may be warranted).
 - Postmenstrual age of 45 weeks and no type 1 ROP (previously called “prethreshold”) disease (defined as stage 3 ROP in zone II, any ROP in zone I) or worse ROP is present.
 - If anti-VEGF injectable medications were used to cause regression of the ROP, postmenstrual age of at least 65 weeks, because this treatment alters the natural history of this disease. Very late recurrences of proliferative ROP have been reported,^{19–21} so caution and clinical judgment are required to determine when surveillance can be safely terminated in individual cases. Infants treated with anti-VEGF medications need particularly close follow-up during the time of highest risk for disease reactivation, between postmenstrual age 45 to 55 weeks.
 - Regression of ROP²² (care must be taken to be sure that there is no abnormal vascular tissue present that is capable of reactivation and progression in zone II or III).
6. The use of digital photographic retinal images that are captured and sent for remote interpretation is a developing alternative approach to ophthalmoscopic ROP screening^{23,24}; however, few outcome comparisons between

large-scale operational digital-imaging systems with remote interpretation versus binocular indirect ophthalmoscopy have been published.²⁵ Nevertheless, some neonatal centers are conducting remote ROP screening for infants still in the hospital.^{23,24} At a minimum, programs that use this method should comply with the timing and other recommendations outlined in the preceding guidelines as well as have capacity for timely bedside examinations if images are ambiguous or be able to promptly transfer to a hospital that can provide this examination. Protocol modifications may be required to allow for additional time for communication, processing, transportation, or other logistical issues,^{26,27} with no time added to the timing noted below for treatment. Captured images and their interpretations should be incorporated into the permanent medical record. It is also recommended that indirect ophthalmoscopy be performed at least once by a qualified ophthalmologist before treatment or termination of acute-phase screening of ROP for infants at risk for ROP. A technical report in which authors have outlined the requirements for a safe program of remote photo screening for ROP has been published by the sponsoring organizations of this policy statement.²³

Digital image capture (taking of retinal photographs) requires skill, experience, broad understanding of the infant eye, and knowledge of ROP (zone, stage, and plus). Ophthalmologists who perform remote interpretation of screening photos for ROP should have the same training requirements as bedside examiners as well as experience in the interpretation of digital images for ROP. Interpretation requires

not only expert knowledge about ROP but also understanding of the limitations of interpreting static images and the special care that must be taken to schedule more frequent imaging sessions that may be required because of those limitations. Remote ophthalmologist interpreters must provide timely clinical input on the timing of follow-up imaging sessions and ophthalmoscopic examinations using appropriate methodology. These findings must be communicated in a manner that is compliant with rules of the Health Insurance Portability and Accountability Act (HIPAA) and other federal and state legal requirements.

Digital retinal imaging may also be a useful tool for objective documentation of retinal findings and for teaching NICU staff and parents about examination results, even if it is not the primary method used for ROP screening in the NICU.²⁸

ROP care that includes off-site image interpretation by ophthalmologists requires close collaboration among neonatologists, imaging staff, and examining ophthalmologists. As with all ROP screening programs, specific responsibilities of each individual must be carefully delineated in a protocol written in advance so that repeat imaging and/or confirmatory examinations and required treatments can be performed without delay.

Treatment

- The presence of plus disease (defined as abnormal dilation and tortuosity of the posterior retinal blood vessels in 2 or more quadrants of the retina meeting or exceeding the degree of abnormality represented in reference photographs^{1,8}; see below) in zones I or II indicates

that treatment, rather than observation, is appropriate.^{7,13}

- Treatment should be initiated for the following retinal findings that characterize Type 1 ROP:
 - Zone I ROP: any stage with plus disease;
 - Zone I ROP: stage 3, no plus disease; and
 - Zone II: stage 2 or 3 with plus disease.
- Practitioners involved in the ophthalmologic care of preterm infants should be aware that the presence of the retinal findings requiring strong consideration of ablative treatment were revised according to the Early Treatment of Retinopathy of Prematurity Randomized Trial study.⁷ This recommendation is based on the findings of improved visual outcomes with earlier treatment recommended by the Final Visual Acuity Results in the Early Treatment of Retinopathy of Prematurity Study.²⁹ “Threshold ROP,” a term that refers to specific morphologic features defined in the Multicenter Trial of Cryotherapy for Retinopathy of Prematurity, is no longer the least severe ROP for which intervention should be considered. “Threshold ROP,” as defined in the Multicenter Trial of Cryotherapy for Retinopathy of Prematurity study, is now included in type 1 ROP, as are certain levels of what was previously known as prethreshold disease that also respond better to ablative treatment than to observation.⁷
 - Special care must be used in determining the zone of disease. The authors of the “International classification of retinopathy of prematurity revisited” provide specific examples on how to identify zone I and zone II disease by using binocular indirect ophthalmoscopy;
 - As noted previously, the presence of plus disease, rather than the number of clock hours of disease, is the better determining factor in recommending ablative treatment;
 - Treatment should generally be accomplished as soon as possible, at least within 72 hours of determination of the presence of treatable disease, in order to minimize the risk of retinal detachment; and
 - Follow-up is recommended in 3 to 7 days after laser photocoagulation or anti-VEGF injection to ensure that there is no need for additional laser treatment in areas where ablative treatment was not complete or additional anti-VEGF injection.
 - Anti-VEGF treatment may hold great promise in the treatment of type 1 ROP. Recently published data³⁰ indicate that intravitreal bevacizumab monotherapy, as compared with conventional laser therapy, in infants with stage 3+ ROP is effective in and may offer significantly improved structural results compared with laser ablation for zone I but not for zone II disease. Development of peripheral retinal vessels continues after treatment with intravitreal bevacizumab, whereas conventional laser therapy led to permanent ablation of the peripheral retina, although authors of published studies indicate that this apparent destruction was associated with only a modest visual field loss. This trial³⁰ was too small to assess the safety and effects on future development of the brain and other tissues. Additional studies are also currently being conducted with other anti-VEGF agents, including ranibizumab (Lucentis). Consideration may be given to

treatment of infants with zone I, stage 3+ ROP with intravitreal injection of bevacizumab. However, practitioners using this therapy should be aware that neither bevacizumab nor other anti-VEGF substances is currently approved by the US Food and Drug Administration for the treatment of ROP.

o If intravitreal injection of bevacizumab or other anti-VEGF agents for zone I stage 3+ ROP is contemplated, it is essential that treatment be administered only after obtaining a detailed informed consent because there remain unanswered questions involving dosage, timing, safety, and visual and systemic outcomes. Whether there are neurodevelopmental complications related to this treatment remains to be seen. To date, studies have yielded contrary findings, with 1 publication³¹⁻³³ reporting increased incidence of neurodevelopmental problems, including severe cerebral palsy, hearing loss, and bilateral blindness, in preterm infants treated with bevacizumab compared with infants whose ROP was treated with laser peripheral ablation alone, but another publication revealed no such effect.³⁴ In addition, reports indicate that there might be less myopic progression in infants treated with bevacizumab compared with infants treated with laser ablation, although long-term comparisons between laser and bevacizumab therapy are lacking.^{35,36}

- Infants treated with bevacizumab injection should be monitored closely after injection by using techniques in accord with these ROP examination guidelines until retinal vascularization is completed or, if not completed,

until the examiner can be assured that reactivation of proliferative ROP will not occur. In the BEAT-ROP study,³⁰ recurrence of ROP after bevacizumab injection tended to occur considerably later than after conventional laser peripheral retinal ablative treatment (16 ± 4.6 vs 6.2 ± 5.7 weeks); therefore, longer follow-up is required for infants treated with bevacizumab to ensure that ROP requiring treatment does not recur. Long-term follow-up of the BEAT-ROP cohort revealed the time frame of highest disease reactivation was between 45 and 55 weeks' postmenstrual age, with 1 AP-ROP case reactivating at 64 weeks' postmenstrual age.^{31,37} There are additional reports^{25,31,35,36,38} of recurrence requiring retreatment as late as 65 to 70 weeks' postmenstrual age.

o Infants treated with intravitreal injection of bevacizumab or ranibizumab alone, therefore, require special caution in the decision to conclude regular retinal examinations. Because of the propensity for late reactivation of significant proliferative disease, one cannot rely on the findings of initial ROP regression or the achievement of 45 weeks' postmenstrual age. Full retinal vascularization is the only criterion listed above that can be relied on as a valid conclusion point. However, full retinal vascularization is not always achieved in infants treated with these agents alone. Under these circumstances, the examiner will have to rely on prolonged observation, clinical judgment, and evolving criteria in the literature for termination of examinations or a need for further treatment.³

- Communication with parents by members of the care team is important, as is documentation of those communications.

Parents should be aware of ROP examinations and should be informed if their child has ROP, with subsequent updates on ROP progression, and should be aware of the possibility of blindness if they do not adhere to the examination schedule after discharge. The possible consequences of serious ROP should be discussed at the time that a significant risk of poor visual outcome develops. Documentation of such conversations with parents in the nurse or physician notes is highly recommended, as is the use of standardized parental educational materials.

- Responsibility for examination and follow-up of infants at risk for ROP must be carefully defined by the staff and consultants of each NICU. Unit-specific criteria with respect to birth weight and gestational age for examination for ROP should be established for each NICU by consultation and agreement between neonatology and ophthalmology services. These criteria should be recorded and should automatically trigger ophthalmologic examinations or photographic documentation with transmission for reading if remote digital camera screening for ROP is used.

Follow-up and Transition of Care

- If hospital discharge or transfer to another neonatal unit or hospital is contemplated before retinal development into anterior zone III has taken place, or if the infant has been treated for ROP and there is either incomplete regression or incomplete retinal healing or maturation, follow-up must be arranged before the infant's departure from the hospital, including ensuring the availability of appropriate ophthalmologic follow-up; specific arrangement

for that examination must be made before such discharge or transfer occurs. The transferring or discharging pediatrician, after consultation with the examining ophthalmologist, has the responsibility for communicating to the receiving physician what eye examinations are needed and their required timing. By review of the medical record and communication with the transferring and/or discharging pediatrician, as appropriate, the receiving physician should ascertain the current ocular examination status of the infant. This period of review and communication before discharge or transfer provides the opportunity for any necessary examinations by an ophthalmologist with ongoing experience and expertise in examination of preterm infants for ROP to be arranged at the appropriate time at the receiving facility or on an outpatient basis if discharge is contemplated before the need for continued examination has ceased, as outlined in recommendation 5 and in the section above on treatment with anti-VEGF agents. For infants managed by using remote photo screening, especially those treated with anti-VEGF agents, outpatient remote photo screening is not currently available. In these cases, examination with indirect ophthalmoscopy is the only option available, and these follow-up examinations must be arranged before discharge.

- It is strongly recommended that the hospital staff arrange and schedule the first postdischarge outpatient ophthalmology appointment with a physician trained in ROP care before the infant's discharge from

the hospital. If responsibility for arranging follow-up ophthalmologic care after discharge is delegated to the parents, they must be made to understand the potential for severe visual loss, including blindness; that there is a critical examination time schedule to be met if treatment is to be successful; and that timely follow-up examination is essential to successful treatment. This information should be communicated both verbally and in writing and should be carefully documented in the infant's medical record. If such arrangements for communication and follow-up after transfer or discharge cannot be made, the infant should not be discharged until appropriate follow-up examination can be arranged by the unit staff who are discharging the infant.

- Regardless of whether infants at risk develop treatment-requiring ROP, pediatricians and other physicians who care for infants who have had ROP should be aware that these infants are at increased risk for other seemingly unrelated visual disorders, such as strabismus, amblyopia, high refractive errors, cataracts, and glaucoma. Ophthalmologic follow-up for these potential problems after discharge from the NICU is indicated within 4 to 6 months after discharge.

This statement replaces the previous statement on ROP from the American Academy of Pediatrics, American Academy of Ophthalmology, American Association for Pediatric Ophthalmology and Strabismus, and American Association of Certified Orthoptists³⁹; ROP care is evolving, and recommendations may be

modified as additional data about ROP risk factors, treatments, and long-term outcomes are published.

LEAD AUTHOR

Walter M. Fierson, MD, FAAP

SUBCOMMITTEE ON RETINOPATHY OF PREMATURITY, 2015–2018

Walter M. Fierson, MD, FAAP, Chairperson
 Michael F. Chiang, MD, FAAP
 William Good, MD, FAAP
 Dale Phelps, MD, FAAP
 James Reynolds, MD, FAAP
 Shira L. Robbins, MD, FAAP

SECTION ON OPHTHALMOLOGY EXECUTIVE COMMITTEE, 2017–2018

Daniel J. Karr, MD, FAAP, Chairperson
 Geoffrey E. Bradford, MD, FAAP, Chairperson-Elect
 Kanwal Nischal, MD, FAAP
 John Roarty, MD, FAAP
 Steven E. Rubin, MD, FAAP
 Donny Won Suh, MD, FAAP
 Sharon S. Lehman, MD, FAAP, Immediate Past Chair
 George S. Ellis, Jr, MD, FAAP, Section Historian

LIAISONS

Pamela Erskine Williams, MD, FAAP – *American Academy of Ophthalmology*
 Gregg T. Lueder, MD, FAAP – *American Academy of Ophthalmology Council*
 Christie L. Morse, MD, FAAP – *American Association for Pediatric Ophthalmology and Strabismus*
 Sarah MacKinnon, MSc, OC(C), COMT – *American Association of Certified Orthoptists*

STAFF

Jennifer G. Riefe, MEd

ABBREVIATIONS

AP-ROP: aggressive posterior retinopathy of prematurity
 HIPAA: Health Insurance Portability and Accountability Act
 ICROP: International Classification of Retinopathy of Prematurity Revisited
 ROP: retinopathy of prematurity
 VEGF: vascular endothelial growth factor

FINANCIAL DISCLOSURE: The lead author has indicated he has no financial relationships relevant to this article to disclose. Committee member Dr Chiang has disclosed the following: a research relationship with the National Institutes of Health, a research relationship with the National Science Foundation, a consulting relationship with Novartis (member of the Steering Committee for the RAINBOW study, which is an international, multicenter, Novartis-sponsored trial involving anti-vascular endothelial growth factor for retinopathy of prematurity treatment), and stock ownership relationship with Intelere retina, a company that is beginning to provide telemedicine services for diabetic retinopathy in Hawaii.

FUNDING: No external funding.

POTENTIAL CONFLICT OF INTEREST: The lead author has indicated he has no potential conflicts of interest to disclose. Committee member Dr Chiang has disclosed the following: an advisory board relationship with Clarity Medical Systems (unpaid).

REFERENCES

1. Cryotherapy for Retinopathy of Prematurity Cooperative Group. Multicenter trial of cryotherapy for retinopathy of prematurity. Preliminary results. *Arch Ophthalmol*. 1988;106(4):471–479
2. Palmer EA, Hardy RJ, Dobson V, et al; Cryotherapy for Retinopathy of Prematurity Cooperative Group. 15-year outcomes following threshold retinopathy of prematurity: final results from the multicenter trial of cryotherapy for retinopathy of prematurity. *Arch Ophthalmol*. 2005;123(3):311–318
3. McNamara JA, Tasman W, Brown GC, Federman JL. Laser photocoagulation for stage 3+ retinopathy of prematurity. *Ophthalmology*. 1991;98(5):576–580
4. Hunter DG, Repka MX. Diode laser photocoagulation for threshold retinopathy of prematurity. A randomized study. *Ophthalmology*. 1993;100(2):238–244
5. Laser ROP Study Group. Laser therapy for retinopathy of prematurity. *Arch Ophthalmol*. 1994;112(2):154–156
6. Iverson DA, Trese MT, Orgel IK, Williams GA. Laser photocoagulation for threshold retinopathy of prematurity. *Arch Ophthalmol*. 1991;109(10):1342–1343
7. Early Treatment for Retinopathy of Prematurity Cooperative Group. Revised indications for the treatment of retinopathy of prematurity: results of the early treatment for retinopathy of prematurity randomized trial. *Arch Ophthalmol*. 2003;121(12):1684–1694
8. Gilbert C, Fielder A, Gordillo L, et al; International NO-ROP Group. Characteristics of infants with severe retinopathy of prematurity in countries with low, moderate, and high levels of development: implications for screening programs. *Pediatrics*. 2005;115(5). Available at: www.pediatrics.org/cgi/content/full/115/5/e518
9. Gilbert C. Retinopathy of prematurity: a global perspective of the epidemics, population of babies at risk and implications for control. *Early Hum Dev*. 2008;84(2):77–82
10. International Committee for the Classification of Retinopathy of Prematurity. The international classification of retinopathy of prematurity revisited. *Arch Ophthalmol*. 2005;123(7):991–999
11. Palmer EA, Flynn JT, Hardy RJ, et al; The Cryotherapy for Retinopathy of Prematurity Cooperative Group. Incidence and early course of retinopathy of prematurity. *Ophthalmology*. 1991;98(11):1628–1640
12. LIGHT-ROP Cooperative Group. The design of the multicenter study of light reduction in retinopathy of prematurity (LIGHT-ROP). *J Pediatr Ophthalmol Strabismus*. 1999;36(5):257–263
13. Hutchinson AK, Saunders RA, O'Neil JW, Lovering A, Wilson ME. Timing of initial screening examinations for retinopathy of prematurity. *Arch Ophthalmol*. 1998;116(5):608–612
14. Reynolds JD, Hardy RJ, Kennedy KA, Spencer R, van Heuven WA, Fielder AR; Light Reduction in Retinopathy of Prematurity (LIGHT-ROP) Cooperative Group. Lack of efficacy of light reduction in preventing retinopathy of prematurity. *N Engl J Med*. 1998;338(22):1572–1576
15. Reynolds JD, Dobson V, Quinn GE, et al; CRYO-ROP and LIGHT-ROP Cooperative Study Groups. Evidence-based screening criteria for retinopathy of prematurity: natural history data from the CRYO-ROP and LIGHT-ROP studies. *Arch Ophthalmol*. 2002;120(11):1470–1476
16. Löfqvist C, Andersson E, Sigurdsson J, et al. Longitudinal postnatal weight and insulin-like growth factor I measurements in the prediction of retinopathy of prematurity. *Arch Ophthalmol*. 2006;124(12):1711–1718
17. Cao JH, Wagner BD, Cerda A, et al. Colorado retinopathy of prematurity model: a multi-institutional validation study. *J AAPOS*. 2016;20(3):220–225
18. Binenbaum G, Ying GS, Quinn GE, et al. The CHOP postnatal weight gain, birth weight, and gestational age retinopathy of prematurity risk model. *Arch Ophthalmol*. 2012;130(12):1560–1565
19. Snyder LL, Garcia-Gonzalez JM, Shapiro MJ, Blair MP. Very late reactivation of retinopathy of prematurity after monotherapy with intravitreal bevacizumab. *Ophthalmic Surg Lasers Imaging Retina*. 2016;47(3):280–283
20. Mehta S, Hubbard GB III. Delayed recurrent neovascularization and persistent avascular retina following intravitreal bevacizumab for retinopathy of prematurity. *Retin Cases Brief Rep*. 2013;7(3):206–209
21. Hajrasouliha AR, Garcia-Gonzales JM, Shapiro MJ, Yoon H, Blair MP. Reactivation of retinopathy of prematurity three years after treatment with bevacizumab. *Ophthalmic Surg Lasers Imaging Retina*. 2017;48(3):255–259
22. Repka MX, Palmer EA, Tung B; Cryotherapy for Retinopathy of Prematurity Cooperative Group. Involution of retinopathy of prematurity. *Arch Ophthalmol*. 2000;118(5):645–649
23. Fierson WM, Capone A Jr; American Academy of Pediatrics Section on Ophthalmology; American Academy of Ophthalmology, American Association of Certified Orthoptists. Telemedicine for evaluation of retinopathy of

- prematurity. *Pediatrics*. 2015;135(1). Available at: www.pediatrics.org/cgi/content/full/135/1/e238
24. Lorenz B, Spasovska K, Elflein H, Schneider N. Wide-field digital imaging based telemedicine for screening for acute retinopathy of prematurity (ROP). Six-year results of a multicentre field study. *Graefes Arch Clin Exp Ophthalmol*. 2009;247(9):1251–1262
 25. Quinn GE, Ying GS, Daniel E, et al; e-ROP Cooperative Group. Validity of a telemedicine system for the evaluation of acute-phase retinopathy of prematurity. *JAMA Ophthalmol*. 2014;132(10):1178–1184
 26. Silva RA, Murakami Y, Lad EM, Moshfeghi DM. Stanford University network for diagnosis of retinopathy of prematurity (SUNDRP): 36-month experience with telemedicine screening. *Ophthalmic Surg Lasers Imaging*. 2011;42(1):12–19
 27. Chiang MF, Wang L, Busuioac M, et al. Telemedical retinopathy of prematurity diagnosis: accuracy, reliability, and image quality. *Arch Ophthalmol*. 2007;125(11):1531–1538
 28. Scott KE, Kim DY, Wang L, et al. Telemedical diagnosis of retinopathy of prematurity intraphysician agreement between ophthalmoscopic examination and image-based interpretation. *Ophthalmology*. 2008;115(7):1222–1228. e3
 29. Good WV, Hardy RJ, Dobson V, et al; Early Treatment for Retinopathy of Prematurity Cooperative Group. Final visual acuity results in the early treatment for retinopathy of prematurity study. *Arch Ophthalmol*. 2010;128(6):663–671
 30. Mintz-Hittner HA, Kennedy KA, Chuang AZ; BEAT-ROP Cooperative Group. Efficacy of intravitreal bevacizumab for stage 3+ retinopathy of prematurity. *N Engl J Med*. 2011;364(7):603–615
 31. Honda S, Hirabayashi H, Tsukahara Y, Negi A. Acute contraction of the proliferative membrane after an intravitreal injection of bevacizumab for advanced retinopathy of prematurity. *Graefes Arch Clin Exp Ophthalmol*. 2008;246(7):1061–1063
 32. Morin J, Luu TM, Superstein R, et al; Canadian Neonatal Network and the Canadian Neonatal Follow-Up Network Investigators. Neurodevelopmental outcomes following bevacizumab injections for retinopathy of prematurity. *Pediatrics*. 2016;137(4):e20153218
 33. Quinn GE, Darlow BA. Concerns for development after bevacizumab treatment of ROP. *Pediatrics*. 2016;137(4):e20160057
 34. Araz-Ersan B, Kir N, Tuncer S, et al. Preliminary anatomical and neurodevelopmental outcomes of intravitreal bevacizumab as adjunctive treatment for retinopathy of prematurity. *Curr Eye Res*. 2015;40(6):585–591
 35. Geloneck MM, Chuang AZ, Clark WL, et al; BEAT-ROP Cooperative Group. Refractive outcomes following bevacizumab monotherapy compared with conventional laser treatment: a randomized clinical trial. *JAMA Ophthalmol*. 2014;132(11):1327–1333
 36. Hu J, Blair MP, Shapiro MJ, Lichtenstein SJ, Galasso JM, Kapur R. Reactivation of retinopathy of prematurity after bevacizumab injection. *Arch Ophthalmol*. 2012;130(8):1000–1006
 37. Mintz-Hittner HA, Geloneck MM, Chuang AZ. Clinical management of recurrent retinopathy of prematurity after intravitreal bevacizumab monotherapy. *Ophthalmology*. 2016;123(9):1845–1855
 38. Zepeda-Romero LC, Liera-Garcia JA, Gutiérrez-Padilla JA, Valtierra-Santiago CI, Avila-Gómez CD. Paradoxical vascular-fibrotic reaction after intravitreal bevacizumab for retinopathy of prematurity [published correction appears in *Eye (Lond)*. 2010;24(1):202]. *Eye (Lond)*. 2010;24(5):931–933
 39. Fierson WM; American Academy of Pediatrics Section on Ophthalmology; American Academy of Ophthalmology; American Association for Pediatric Ophthalmology and Strabismus; American Association of Certified Orthoptists. Screening examination of premature infants for retinopathy of prematurity. *Pediatrics*. 2013;131(1):189–195