SKERI Smith-Kettlewell Eye Research Institute

# Mapping the binocular scotoma in macular degeneration

Cécile Vullings & Preeti Verghese

## INTRODUCTION

When the scotoma is binocular, it often obscures objects of interest, causing individuals with macular degeneration (MD) to miss information. Furthermore, the majority of individuals with MD are unaware of their scotoma, which causes further difficulties in tasks of daily living.

Here, we propose a method to map precisely the binocular scotoma.

### Bilateral macular degeneration

Monocular scotomas (SLO/OCT)
Vertically flipped on the retina




## METHODS

### Step 1: Screening

Visual acuity - Contrast sensitivity - Stereoacuity - Peripheral retinal loci (SLO) - Extent of monocular scotomas (SLO) - Location of foveal pits (OCT)

Participants: 6 with a binocular scotoma (B; age: 56-89), 3 with monocular scotomas (M; age: 75-79) and 3 controls (C; age: 61-74)

### Step 2: Binocular scotoma mapping

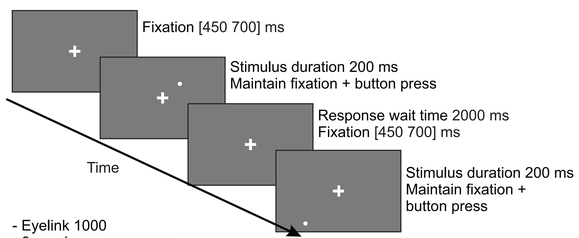


- Eyelink 1000
- 6 sessions, on average
- Fixation criterion based on fixation stability
- 35 locations probed twice per session
- Coarse-to-fine grid to probe visual field (40.36° x 30.27°)

### Step 3: SLO-based binocular scotoma estimate (Ghahghaei & Walker, 2016)

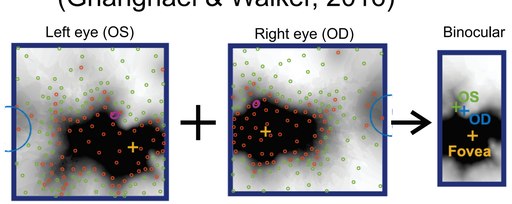


*1) The monocular data were modelled using a nearest k (k=10).*

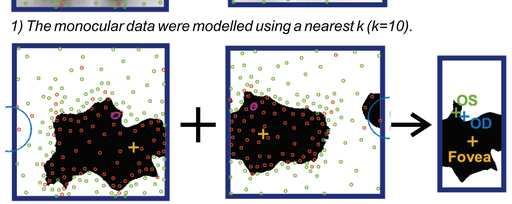


*2) The monocular maps were fitted according a variable threshold (here, t=0.5).*

The algorithm uses the perimetry, fixation locus and foveal pit location from the SLO/OCT (21° x 21°). The area of the binocular scotoma was estimated by aligning the monocular data on the foveal pits of each eye.

## RESULTS

### Coarse-to-fine manual selection of probed locations yields fine details of scotoma edges

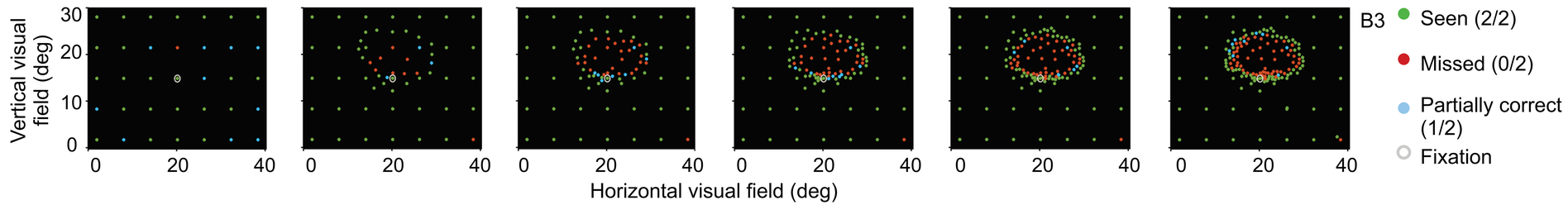


### The size and shape of monocular scotoma from the eye-tracker is similar to the SLO map

*Mapping the blindspot with control participants*

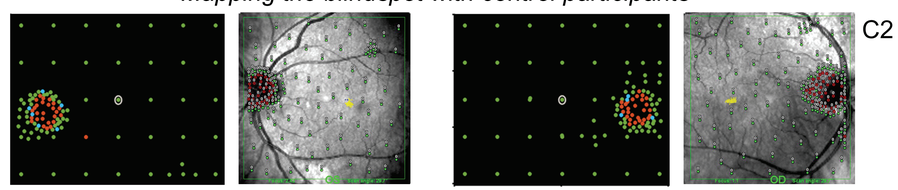


*Mapping the monocular scotoma with B and M participants*




### The size and shape of binocular scotoma from the eyetracker is similar to the estimate from the Ghahghaei-Walker algorithm

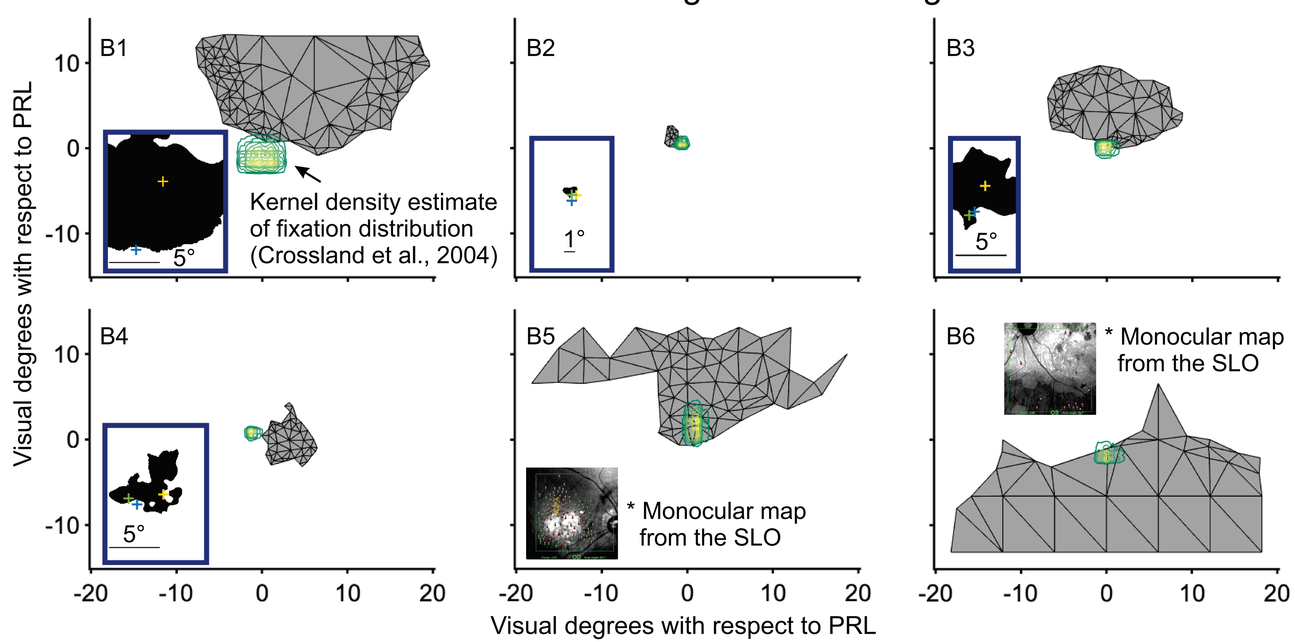


### Fixation loci were tightly clustered for all participants

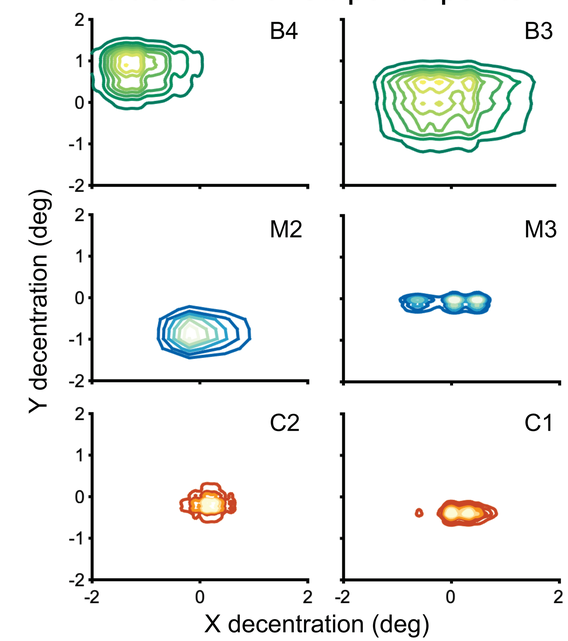


## CONCLUSIONS

- A regular eyetracker can be used to reliably and precisely assess the residual functional retina in binocular vision.
- Determining the size and location of the binocular scotoma with respect to the fixation locus is key for assessing and training an appropriate strategy for eye movements in age-related macular degeneration.

## ACKNOWLEDGEMENTS

We would like to thank Dr. Saeideh Ghahghaei for providing the script of the algorithm from Ghahghaei & Walker (2016) and Dr. Don Fletcher for referring the patients who participated in this study.
This work was supported by a Fulbright grant (CV) and a NIH grant NIH R01 EY029730 (PV).

FULBRIGHT COMMISSION FRANCO-AMÉRICAINE

## REFERENCES

Ghahghaei & Walker (2016). SKERI-Optos: A graphical user interface to map scotoma and PRL with the Optos OCT/SLO. *Journal of Vision, 16(4)*, 40-41.
Crossland, Sims, Galbraith & Rubin (2004). Evaluation of a new quantitative technique to assess the number of and extent of preferred retinal loci in macular disease. *Vision Research, 44*, 1537-1546.

**Contact:** cvullings@ski.org