

CURRENT TECHNIQUES OF ADJUSTABLE STRABISMUS SURGERY

ARTHUR JAMPOLSKY, M.D.

San Francisco, California

An adjustable strabismus surgical suture technique is one in which an alteration in result may be made immediately postoperatively for both the primary position balance and rotational balance. This adjustment is made when the patient is fully alert and attentive, and the surgeon may monitor the adjustment by directly observing the usual cover test results for the primary position and other non-primary rotational positions.

The technique to be described here is one in which absorbable sutures are placed under conditions of general anesthesia, and the alterations and adjustments made postoperatively when full innervational active tonus components are present.

The selected surgical goal may be one of exact alignment, undercorrection, or deliberate overcorrection. Whatever the goal, it may be adjusted to achieve the desired surgical result more accurately. One combines the accepted monitoring and measuring guides in an alert patient, with an accepted surgical method of repositioning muscles, to attain the selected surgical goal better and to minimize the number of surgical procedures (ideally to a single procedure).

The problem of long-term stability of surgical result is another problem involving different relevant sensorimotor relationships or long-term mechanical changes, or both, that may be present in any type of surgical procedure.

Adjustable procedures provide an im-

mediate opportunity to alter the surgical best estimate of muscle repositioning, especially where such estimates are unusually difficult, such as in cases with unusual anatomic changes (as in reoperations), and in cases with unusual and less predictable active tonus force factors. We merely wish to extend the usual surgical procedure into the postoperative period (same hospitalization) so that there may be satisfactory monitoring of the final surgical result.

Indications—Adjustable techniques should be considered whenever a desired goal is unlikely to be reached in one surgical session. There are a variety of reasons for this, the most common being an unusual, or a relatively unpredictable, relevant factor that makes an estimation of the final surgical result less than optimal.

Some indications are as follows:

1. A precise balance result is mandatory. An example is adult thyroid myopathy of an asymmetrical amount, in which each inferior rectus muscle must be recessed a different more-than-usual amount, and may be combined with medial rectus muscle recessions of the same type. Such acquired adult strabismus requires perfect results.

2. Repeated operations are being performed, wherein abnormal muscles and surrounding muscle mechanics are so altered as to disallow accurate estimation of the resultant balance of forces.

3. A goal of rotational balances (comitancy) may be in conflict with the goal of primary position alignment, and a trade-off is possible with adjustable sutures.

4. Excessive amounts of surgery may be necessary, and the surgeon may wish to alter muscle placement. An example is

From the Smith-Kettlewell Institute of Visual Sciences, San Francisco, California. This study was supported in part by The Smith-Kettlewell Eye Research Foundation.

Reprint requests to Arthur Jampolsky, M.D., Smith-Kettlewell Institute of Visual Sciences, 2232 Webster St., San Francisco, CA 94115.

a larger than usual recession for secondary overshoot of a muscle in a variety of circumstances.

5. Partial forces need to be balanced. This is one of the most difficult problems in strabismus alignment; for example, muscle transposition procedures for paresis, recessing both agonist and antagonist muscles for balancing anomalous innervations (some Duane's syndromes), and the like.

6. Ciancia's syndrome (adduction fixation preference with increasing abduction nystagmus in infantile esotropia) has unusual and unpredictable active tonus force factors that are present only in the alert state, thus demanding a procedure that allows for adjustment of muscle reposition (force change) postoperatively. In some cases, one may wish to perform a much larger than usual medial rectus recession (as part of the alignment procedure), and a safety factor of alteration during the immediate postoperative period is desirable.

In general, whenever the selected goal will be less probably attained because of unusual mechanical or innervational factors, an adjustable suture technique allows an extension of the surgical procedure to compensate for miscalculations.

*Previous problems and solutions—*Several surgical techniques have been proposed to attain the goal of more accurately adjusting the muscle placements under direct monitoring conditions in an alert patient. Among these have been one-stage topical (conjunctival drop anesthesia only) adjustment procedures,¹ adjustments that are possible in the postoperative period,² in difficult repeated operations,³ and in muscle paralysis and paresis.⁴ These techniques have recently been summarized.⁵

From these several techniques one has emerged that has proved useful for most circumstances wherein an adjustable technique is used on one or more mus-

cles. The technique is applicable for either recession or resection of a muscle, and the same technique is used for adults and children (when indicated).

Some of the previous problems that have been solved by the current technique are as follows: (1) traction on the globe during adjustment, for globe position control, has been obtained by a simple globe "handle" of smooth nonabsorbable suture in the form of a small loop near the corneoscleral limbus; (2) more accurate measurement of millimeters of adjustment by means of the sliding knot technique; (3) greater insistence on anesthesiologist and ancillary personnel cooperation with careful attention to the type of drug administered pre- and postoperatively; and (4) increased attention to details of adequate light during the adjustment and selection of forceps for adjustment.

METHODS

A conjunctival flap is routinely used to bare the sclera where the adjustable scleral suture emerges (Figs. 1 and 2). This allows postoperative manipulation of the muscle suture free of extraneous conjunctival and subconjunctival tissue. The adjustable suture knot does not always absorb well. Thus, we have routinely elected to leave the knot exposed in bare sclera, where it may be excised flush

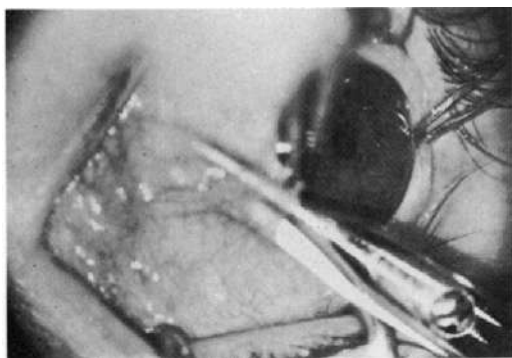


Fig. 1 (Jampolsky). A conjunctival flap, to be recessed, is prepared from a buttonhole at the corneoscleral limbus.

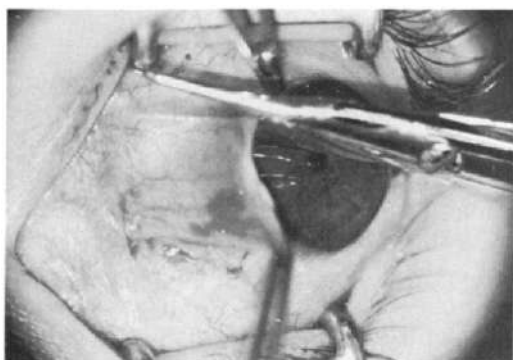


Fig. 2 (Jampolsky). Radial incisions are made so the conjunctival flap may be recessed.

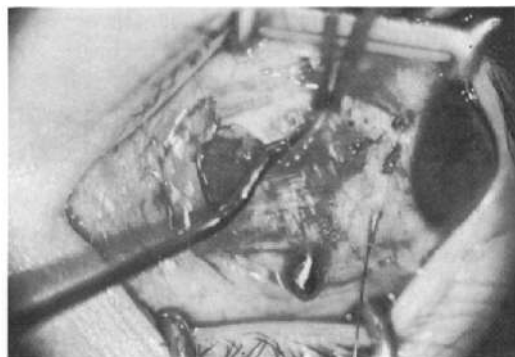


Fig. 3 (Jampolsky). A loop handle is inserted near the corneoscleral limbus with a smooth nonabsorbable suture (Prolene, or nylon 6-0). A completely smooth suture is essential, since a braided suture may cause a slight, but annoying, scleral bleeding when removed postoperatively. A good scleral bite is necessary.

with the sclera two to three weeks postoperatively, for a cosmetically more satisfactory healing result.

A globe control "handle" is placed near the corneoscleral limbus. This loop handle is convenient during surgery for rotating the globe in a desired direction. It is preferred to a traction suture secured to the drape, which may occasionally fall over the cornea. The assistant easily grasps and controls the globe by inserting toothed forceps through the small loop (Figs. 3 and 4). This is a particularly useful and simple surgical device for cases in which the globe may have to be rotated many times during the surgical procedure (strabismus operations, retinal detachments, and the like). The loop handle is used most effectively during the postoperative adjustment, in which globe con-

trol can be easily and painlessly obtained during the adjustment procedure, after which the loop is cut and removed.

The muscle to be recessed is securely locked at each border with a double-armed dyed synthetic absorbable 6-0 suture (Vicryl or Dexon). The suture is locked or tied, or both, according to the surgeon's usual procedure. The tensile strength of these synthetic sutures is remarkably good. The surface of dyed sutures is reasonably smooth, insofar as their ability to slide through the scleral tracts during the adjustment is concerned. Undyed sutures are unsatisfactory for this technique.⁵

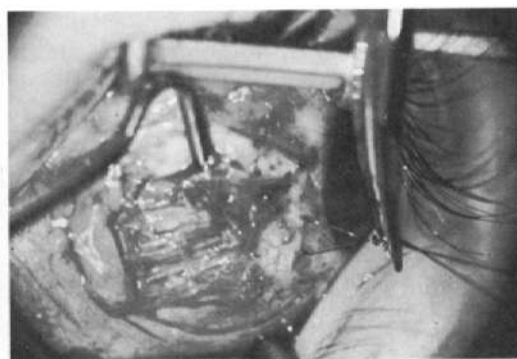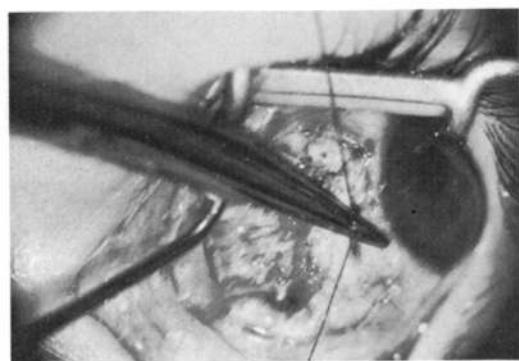


Fig. 4 (Jampolsky). Left, The globe-handle is tied over an instrument tip to form a small loop. Right, The loop is tied with four ties. This loop-handle secures globe stabilization or manipulation with small toothed forceps.

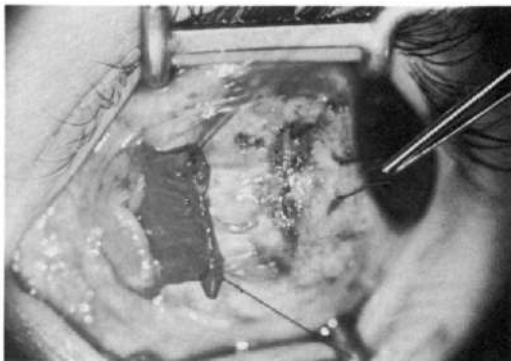


Fig. 5 (Jampolsky). The muscle to be recessed is secured with the surgeon's preferred suture locking technique, then disinserted. The assistant controls the globe via the loop-handle.

The muscle is disinserted (Fig. 5), and the double-armed muscle suture is passed directly through the insertional stump (Figs. 6 and 7). The muscle hangs loose from the insertional area (the recessed muscle ends are not sutured directly to the sclera). With postoperative return of alertness and muscle tonus, the muscle will assume the farthest recessed rest position allowed by the measured suture placement. The muscle retracting force of

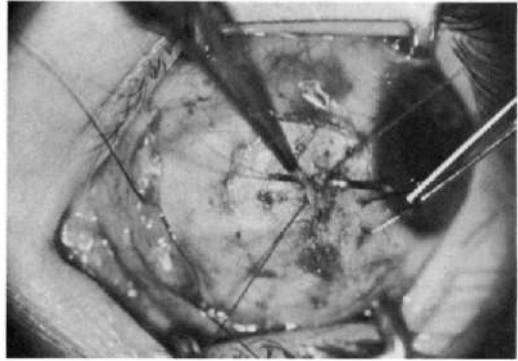


Fig. 6 (Jampolsky). Muscle sutures are placed through the scleral insertion stump so that, after the tracts are slightly enlarged, the two suture ends will emerge from the sclera at almost the same point. Note that the scleral loop-handle is placed somewhat eccentrically, to separate it from the muscle suture manipulation.

active innervation is remarkably demonstrated in those patients operated on under topical (conjunctival sac) anesthesia. It is further demonstrated during the postoperative adjustment stage as active innervation force may be felt against the surgeon's globe fixation through the globe loop handle.

A new scleral insertion attachment may be chosen closer to the corneoscleral limbus, especially for the superior rectus muscle, and, in some cases of repeated operation, to secure better accessibility of suture manipulation during the postoperative adjustment stage. Similarly, if a muscle displacement-transposition is desired, any convenient scleral point reasonably near (but not at) the corneoscleral limbus may be chosen, so that it is separated from the globe fixation loop handle by a reasonable space.

The scleral needle tracts are placed so that the sutures emerge at almost the same point. This is imperative, for it enables the sliding knot to move easily along an adequate length of the emerging muscle sutures. If the muscle sutures do not emerge close together, the sliding knot adjustments will be more difficult, because now the knot will have to constrict

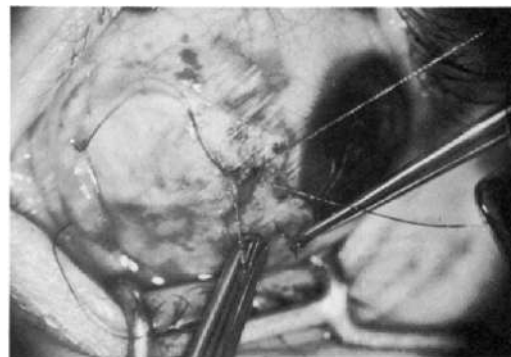


Fig. 7 (Jampolsky). The scleral muscle suture tracts are enlarged by to-and-fro sawing motion of the suture. The anterior emerging suture motion is in line with the suture tract, the posterior entering suture motion saws laterally to enlarge the posterior tract, but not the anterior tract. The assistant steadies the globe by means of the loop-handle. During the scleral tract enlargement, as one moves each muscle suture end to-and-fro, it is advisable to grasp the muscle suture in an area of the suture to be discarded, since the suture material can be squashed with smooth forceps during this maneuver.

the spread muscle sutures as the sliding knot nears their scleral emergence from the separated points of emergence, which are to be avoided.

The scleral suture tracts are now enlarged to assure that the muscle sutures slide easily through them, so as to make the postoperative adjustment of muscle position easy. The scleral suture tracts are enlarged (Fig. 7) by a lateral to-and-fro sawing motion of the suture. Care must be taken not to saw perpendicular to the globe in order to prevent the suture from eroding the length of the tract. This sawing motion is done in such a way that the posterior part of the tract (farthest from the corneoscleral limbus, where the needle entered the sclera) will have an enlarged tract opening, while at the same time minimally enlarging the emergence point of the anterior tract needle (closer to the corneoscleral limbus).

A separate sliding suture is placed around the muscle suture ends so that it constricts sufficiently to prevent slipping, but slides sufficiently to allow postoperative adjustment (Fig. 8). The sliding suture is merely a wraparound suture (of the same material as the muscle suture), which is tied tightly around the muscle sutures and secured with four knot-ties. The ends of this independent sliding su-

ture are cut—one end a few millimeters long (to ensure against unraveling during the sliding adjustment) and the other end approximately 10 mm long (sufficient to grasp with forceps during the sliding adjustment maneuver).

While the sliding suture knot is being tied, the muscle sutures must be held so that the muscle is pulled flush against the scleral tracts. This assures that the lengths of the muscle sutures will remain the same during any sliding knot adjustment maneuver, and that the muscle end will maintain a correct globe orientation (recession or resection).

The tightly tied constricting sliding suture is now slid up and down the muscle suture several times. It is important at this point to make sure that each slide smoothly continues all the way to the scleral tract, and slides up approximately 2 cm (Fig. 9). This essential maneuver should be continued until the knot slides easily, without building up areas of muscle suture material, as might occur with non-continuous, shorter movements. The sliding knot must move easily and comfortably for ease of postoperative adjustment. The adequacy and security of the constricting sliding knot may be tested easily by intrasurgical muscle manipulation.

An initial error is not to secure the

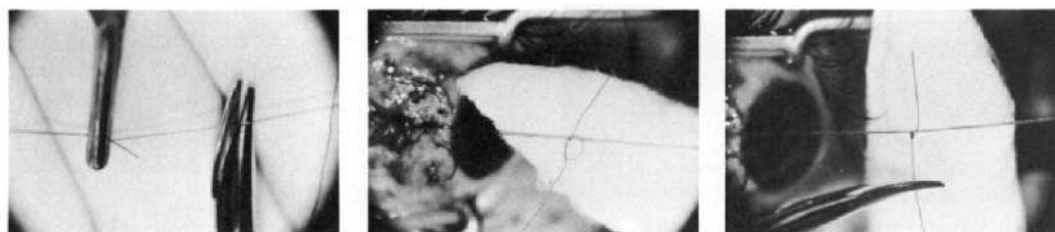


Fig. 8 (Jampolsky). Left, The assistant pulls the muscle sutures at a point 2 to 3 cm from the sclera (to allow sufficient length for postoperative suture tying), with the severed muscle end pulled flush against the scleral tract. This assures that the muscle end border will maintain correct orientation during the sliding suture adjustment procedure. The ends of the muscle sutures are cut at slightly different lengths for ease of separation during adjustment. Center, The sliding knot (of the same suture material as the muscle suture) is tightly tied and secured by four knots. The two muscle suture ends emerge from the sclera at almost the same point, which makes the sliding of the constricting suture easier. Right, The constricting sliding-knot ends are cut so that one end is long enough to grasp with forceps during the adjustment stage, and the shorter end a few millimeters in length to assure that the knot remains tied during the sliding maneuver.

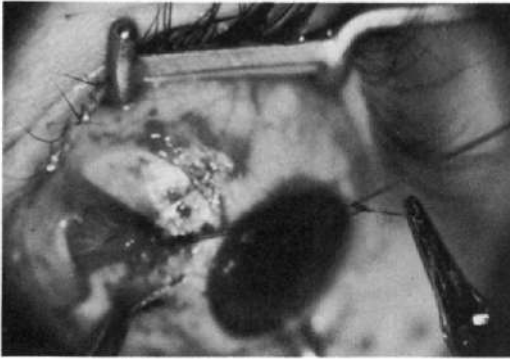


Fig. 9 (Jampolsky). The constricting sliding-suture is moved up and down the muscle suture, in continuous strokes, from the scleral tracts for a distance of 1 to 2 cm of muscle suture. With five to ten such smooth continuous movements, the surgeon will feel the desired amount of friction, which will sufficiently constrict and hold the muscle as the knot is flush against the sclera and be sufficiently loose to make the postoperative adjustment an easy task. Wetting the suture during this maneuver may be helpful.

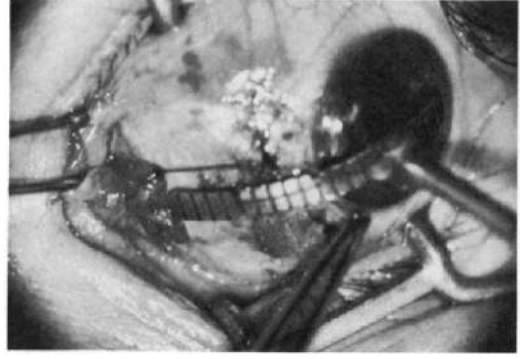


Fig. 10 (Jampolsky). The muscle is allowed to recede a measured amount by appropriate placement of the sliding suture. Note how the muscle becomes spread out as it hangs loose in its recessed position.

sliding knot tightly enough with several ties. The first of the several sliding-loosening maneuvers should be somewhat difficult to initiate, but the repeated sliding maneuvers should become increasingly easy. One stops at the correct constriction-sliding ability.

The amount of recession is easily measured and altered by manipulating the sliding-suture position (Fig. 10). Additional adjustments in muscle position may be made by merely moving the sliding suture a measured number of millimeters in either direction. The same maneuver will be used during the postoperative adjustment repositioning, if indicated.

For recession procedures, the muscle is always allowed to be recessed more than would ordinarily be estimated, since it is easier to make the adjustment by pulling the muscle up (minimizing the recession) postoperatively than it sometimes is to allow the muscle to recess further. The globe loop handle fixation makes the latter maneuver much easier. Such recessions of greater than usual amount have

often proved to be adequate (not requiring adjustment), thus permitting the surgeon a bolder approach in attaining a selected surgical goal.

The conjunctival flap is then recessed and secured to the sclera with 7-0 absorbable gut (Figs. 11 and 12). The interrupted flap-securing sutures are placed so as to prevent anterior encroachment of the flap edge to avoid interference with the muscle sutures.

The nasal conjunctiva and plica require special attention, to make sure that the plica tucks back with nasal globe rotation, and that the nasal cul-de-sac is naturally reformed. This requires closing the dead space between the conjunctiva and medial rectus (or sclera), and is important in most strabismus surgery. A simple mattress suture opposes the conjunctival flap to the medial rectus border (Fig. 11). Care must be taken to avoid a "reverse leash" or a "short sheet" of conjunctiva, which limits adduction. This has been discussed elsewhere.⁶

Once the recessed conjunctival flap is secured to sclera, the muscle suture ends are tucked into the cul-de-sac. An ointment is not applied since it does not add to the ease of muscle suture manipulation during the adjustment tying stage. Telfa,

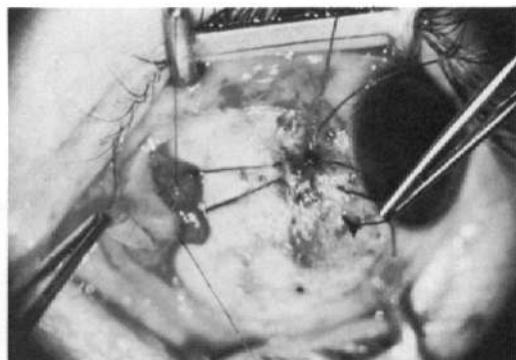
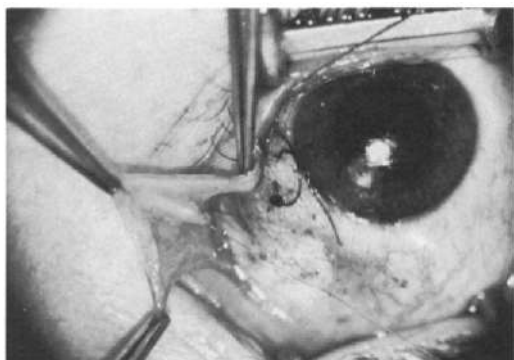


Fig. 11 (Jampolsky). The previously prepared conjunctival flap is recessed and secured to sclera with interrupted 6-0 absorbable gut. A simple mattress suture (6-0 absorbable gut) opposes a suitably selected part of the nasal conjunctiva (left) to be sutured to the anterior part of the medial rectus muscle (right).

or similar material, is placed over the eye and secured with an eye pad.

An adjustable resection procedure may be performed in a similar manner (Figs. 13-18). The conjunctival flap and muscle exposure are performed in the usual manner. A muscle clamp may or may not be used. Figures 13 and 14 show

placement of a single double-armed muscle suture, securely locked at each muscle border. Some surgeons prefer a single adjustable suture for resections, as well as recessions, especially if the resection is small, with modest muscle tension to be controlled. If a large resection is to be performed, or a stiff reoperated muscle under tension is to be controlled, two adjustable sutures are recommended for safe control of the additional muscle tension in most strabismus surgery.

The resected muscle is excised (Figs. 15 and 16). Before cutting, the muscle may be clamped for hemostasis. The resection sutures are placed in the muscle at a point

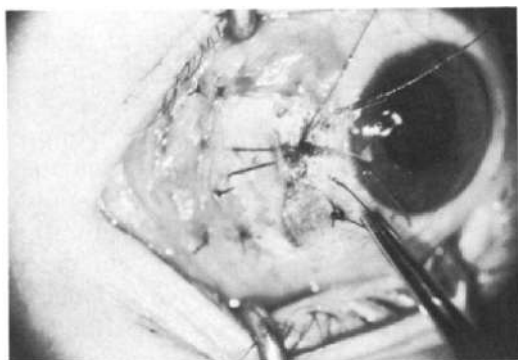


Fig. 12 (Jampolsky). The final stage shows the recessed conjunctival flap secured to the sclera to anchor the corners of the recession (with some conjunctival tension purposely created between the corners), and a single recessed conjunctival border suture to permit free sliding muscle sutures. The bare sclera anterior to the recessed muscle border should be cleaned of all excessive tissue at the time of initial muscle exposure. The insertional stump and all other tissue should be carefully excised to leave a bare white sclera. Remaining (nonexcisable) pink episclera may be lightly cauterized off with sweeping light cautery motion to leave bare white sclera for best cosmetic result. This closure is the same whether one has done an adjustable recession or resection.

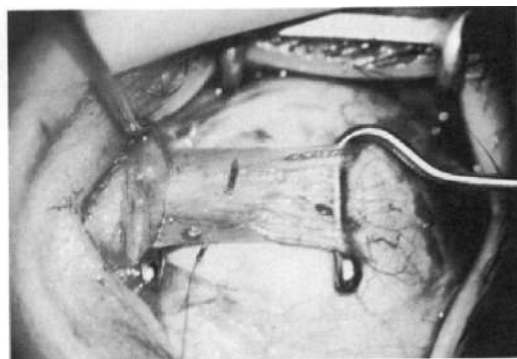


Fig. 13 (Jampolsky). A resection is performed with either a single double-armed suture, or two such double-arm sutures, depending upon the surgeon's preference or the circumstances. The conjunctival flap and muscle exposure are performed in the usual manner.

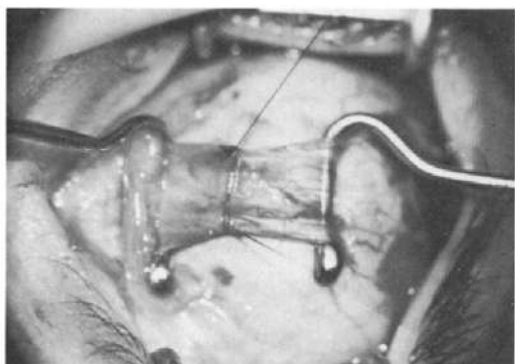


Fig. 14 (Jampolsky). Moderate resection of a normal muscle, for which a single double-armed suture may be used.

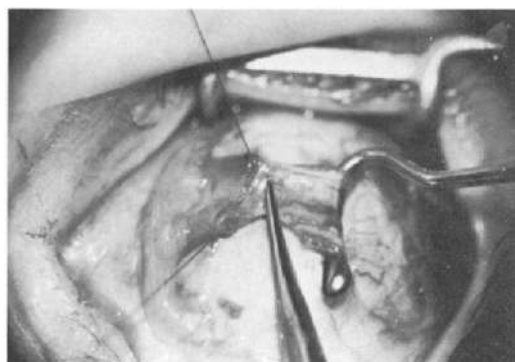


Fig. 15 (Jampolsky). The resected muscle is excised. For better hemostasis, one may clamp the muscle before cutting.

a few millimeters farther than the desired or estimated amount of resection, because the muscle will not be pulled forward flush with the original insertion (which would result in a full amount of resection), but rather is allowed to recess 2 to 3 mm. For example, if it is estimated that 5 mm of resection is desirable, the sutures are placed approximately 7 to 8 mm from the insertion as if 7 mm of resection were to be performed (Figs. 13 and 14). However, the muscle is finally allowed to rest 2 to 3 mm from the original insertion (Fig. 18), resulting in an effective 5-mm resection. During the adjustment stage, more effect may be obtained by advancing the muscle, which increases the muscle tension. Or, the resected muscle can

be allowed to recess even further, thus relaxing muscle tension and altering final muscle attachment position.

Insofar as the lever arm is concerned, it does not matter significantly whether the final attachment is a few millimeters anterior or posterior one way or the other, so long as there is a good and normal lever arm maintained throughout rotations. It is when the final muscle attachment position is unusually posterior, where a diminished lever arm torque may result on further rotation, that these few millimeters matter. It may be important in the

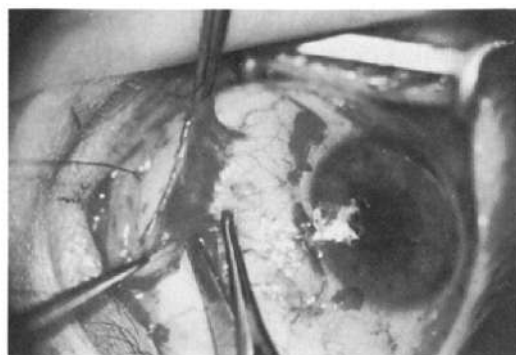


Fig. 16 (Jampolsky). The resected muscle is cut flush with the scleral insertion.

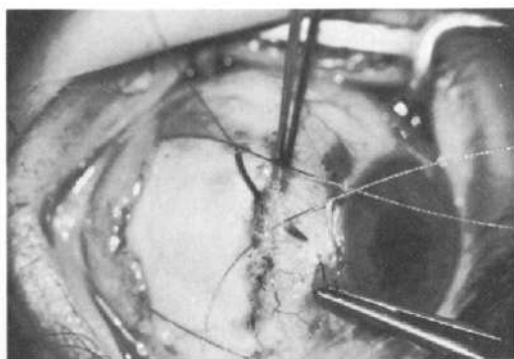


Fig. 17 (Jampolsky). The muscle sutures are placed through the insertional stump, in the same manner as described for the recession procedure (see Figure 6). Note the suture tract emergence points positioned adjacent to each other. After tract enlargement maneuvers, aimed at enlarging the posterior (but not the anterior) part of the tracts, the emerging suture ends emerge practically together.

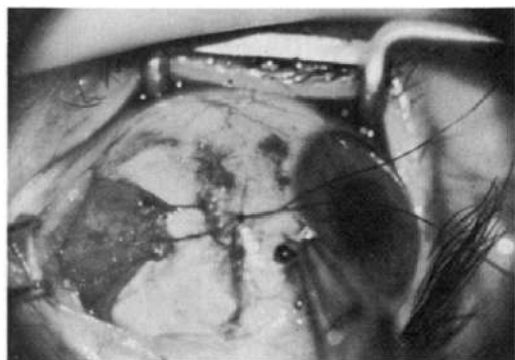


Fig. 18 (Jampolsky). The resected muscle end (which has been purposefully resected slightly more than necessary) is pulled forward toward the previous scleral insertion. However, it is not pulled flush, but rather allowed to remain recessed a few millimeters in order to adjust the resection in either direction.

circumstances of a stiff muscle (poor elasticity range), were its insertion to be retroplaced sufficiently so that the normal arc of contact will not be maintained and a poorer lever arm results. However, for the usual circumstances, as long as there is an adequate lever arm (sufficient anterior final muscle attachment), the alterable variable is muscle tension, which the surgeon manipulates by altering the muscle length (millimeters of surgery).

The postoperative adjustment stage is usually performed on the morning after surgery, or it may be done on the same day (after approximately four to eight hours), if full patient alertness is obtainable. The patient must be fully alert and attentive for an appropriate adjustment to be made because the alerting mechanism plays such a dominant role in oculorotary muscle active innervational force. The slightest hangover effect from barbiturates, anesthesia and postanesthetic drugs, and narcotic pain relievers, all work counter to this goal. One might wish to confine postoperative medication to such drugs as codeine, aspirin, and the like.

The essence of the adjustable procedure is to have operable the net effect of

all usual and natural passive anatomic and active innervational forces. Thus, all systems must be operating as naturally as possible, especially full alertness and attention. Indeed, these are the essential criteria that must always be fulfilled for cover test and rotational monitoring and assessment of the primary position balance and nonprimary rotational balances. The surgeon must exercise judicious care in selecting cooperative and informed anesthesiologists and colleagues to assure that one avoids even mildly undesirable drug effects.

Conjunctival anesthetic drops are instilled several times in both the operated and unoperated eye. The drops reduce induced hypersensitivity and photophobia. The patient sits up in bed, and spectacles are worn as indicated. The balance assessment is made by the usual cover test procedure for the primary position, and for nonprimary rotational positions.

Customarily, the patient is asked to follow a target in several directions of gaze to minimize the muscle hysteresis (or, backlash stiffness). More normalized muscle stiffness is obtained with repeated eye movements in several directions after each adjustment procedure. This is analogous to the normalization of muscle stiffness secured during the spring-back balance test performed during surgery for mechanical balance,⁷ whereby forceps in passive rotations of the eye, repeated several times back and forth, allow stretching and relaxation of the passive muscle forces in order to allow a more normal muscle status for balance assessment.

Adjustment of the muscle position (either a recession or resection) is made by spreading the eyelids with a self-retaining thin wire speculum, or, more commonly, an assistant merely rolls the upper and lower eyelids back with a cotton-tipped applicator. The latter method often gives far better exposure of the superior rectus muscle adjustment than does a speculum.

It is optimal for the surgeon to have a portable head-mounted loupe and light, and properly selected tying forceps. (We currently prefer ordinary inexpensive jeweler's smooth forceps, with the sharp tips modified to a suitably blunted end.)

The muscle is adjusted as dictated by the cover test imbalance or rotation imbalance, or both. These maneuvers may be repeated several times, with repeated muscle adjustments.

To reduce a recession with the sliding-suture technique, the muscle repositioning is accomplished by pulling both ends of the muscle suture (as a unit) to diminish the recession a desired number of millimeters. This may be directly observed as the distance the constricting sliding knot has been moved away from the scleral tract as the muscle sutures are pulled forward. Sometimes the muscle sutures do not slide freely through the enlarged scleral tracts, in which case small-toothed forceps are used to grasp the globe handle for globe stabilization, while the muscle sutures are then easily manipulated. The sliding suture is moved an appropriate number of millimeters, so as to reduce or augment the amount of muscle recession (or advancement). In this fashion, one may finely tune either the primary position balance or a rotational balance.

The surgeon may elect to trade advantages and disadvantages between primary position and rotational balances by using one or more adjustable muscle sutures. Adjustable sutures become a second-guess opportunity for the surgeon especially in cases that are difficult to estimate.

The globe handle is currently used routinely, which allows the surgeon painless, bloodless, and atraumatic control of globe position. Previously, an augmentation of the amount of recession was performed with some difficulty. With the globe handle traction, the sliding knot is moved so

as to allow the desired number of additional millimeters of recession. The patient's own muscle force is allowed to retract the muscle so that the sliding suture is flush with the sclera, by the surgeon's holding the globe by the loop handle and asking the patient to look in the opposite direction. The muscle force so generated easily recesses the muscle the additional amount desired. This was a problem previously, but is now adequately solved by the globe loop handle fixation.

When the cover test and rotation balances have yielded satisfactory results, the adjustments are completed by tying the muscle suture securely with several ties. The excess ends of the muscle sutures and the excess ends of the sliding suture are cut. The globe loop handle is simply removed by cutting at any one point.

Home care consists of evening instillation of antibiotics-corticosteroid ointment and covering with an eye pad. The adjustable suture knot may be somewhat irritating to the unpadded eye. If the muscle suture knot on bare sclera is not absorbed sufficiently by two to three weeks, it is simply cut off flush with the sclera. This is not uncommon for procedures of the medial and lateral rectus muscles. The exposed adjustable suture knot for the superior rectus and inferior rectus muscles, even though not covered by conjunctiva, apparently is sufficiently bathed in warm moisture to disappear satisfactorily without further attention.

*Complications during adjustment—*Rarely, the sliding suture knot may unravel during the adjustment procedure. One simply converts to a bow-knot procedure.^{2,3,5}

Infrequently, the sliding knot may move with difficulty, despite the repeated sliding-loosening maneuvers done during surgery. This is easily overcome by merely separating the two arms of the muscle sutures and spreading them apart

at the apex of the V at the sliding knot. The sliding suture will slide down with this maneuver as the muscle sutures are spread apart, and the millimeters of alteration may be estimated.

Occasionally, when adjustable sutures are used in some children who are less cooperative than anticipated, a short duration of nitrous oxide anesthesia is necessary for the adjustment procedure. When an adjustable suture is used in some infants, the postoperative adjustment is customarily made in the recovery or treatment room. Short nitrous inhalation anesthetic should be given by the same anesthesiologist who administered the general anesthesia. Assessment of primary position and rotational imbalance is made by direct observation while the infant is awake, and gross imbalances are readjusted, but fine-tuning maneuvers are not usually possible.

DISCUSSION

The current adjustable strabismus surgical suture technique, evolved from a modification of older techniques, allows sharpening of management principles with a closer approach to the surgical goal of balanced alignment in the primary position and of balanced rotations with a minimal number of surgical procedures.

Repositioning of muscles at the time of the usual and ordinary surgical procedure is the strabismus surgeon's means of attaining the selected surgical goal, without direct and full monitoring of his final efforts. Adjustable surgical suture procedures do not differ in the method of repositioning of muscles; it merely adds a satisfactory monitoring of the total end result by extending surgery into the immediate postoperative period when the patient is alert.

Whereas initially we believed adjustable techniques were primarily indicated in unusual and unpredictable circumstances (such as for repeated operations),^{2,3}

we now believe that an adjustable muscle technique for at least one muscle is indicated for almost all adult strabismus surgical corrections. In some cases, for instance thyroid myopathy with bilateral asymmetrical inferior rectus contractions, bilateral adjustable sutures afford the only means of achieving the goal of perfect realignment. This is because the muscles in thyroid myopathy surgery are altered in several important factors, such as abnormal muscle stiffness (elasticity range), muscle length, and lever arm (large amounts of recessions are necessary). It is distinctly an unusual strabismus correction task, making adjustable sutures almost mandatory.

The previously listed indications define other groups or classes of strabismus for which results are relatively unpredictable.

Surgical results are certainly not defined by the sole factor of millimeters of surgery performed. Millimeters of recession or resection (under usual circumstances) change the muscle length, which affects muscle tension or force. This is what the surgeon accomplishes under usual and normal conditions in which the muscle has normal stiffness (elasticity range), normal lever arm (is not attached too far posteriorly), and has a normal opposing muscle force operable. Often these assumptions of normality in these several factors are not fulfilled. And these several variables often disallow accurate estimation of results, especially if one depends upon millimeters of surgery alone, which usually affects only one of the variables (muscle tension). In usual and ordinary cases of moderate amounts of strabismus, all the variables and surgical results are relatively predictable. When any one of the factors of muscle force range (stiffness characteristic), force change with muscle length, effective force locale (lever arm), or opposing muscle force is unusual, then surgical results

become unpredictable. Especially in unusual cases of passive mechanical factors, or active innervational factors (especially reoperations), in which all of these variables are not usual, adjustable sutures allow better prediction of the resultant net effects, regardless of the causation or of the ability to assess the designated variables independently and separately. Someday in the near future we will be able to do this in a practical clinical fashion. Strabismus surgeons will find it increasingly necessary to attend to these quantifiable variables for proper strabismus management. Adjustable sutures merely bypass the present state of unpredictability but are certainly no substitute for knowledge of how to assess, monitor, and manipulate the variables that are now known to be relevant.

The following examples highlight the utility of adjustable sutures.

Unusually large eyes (adult myopia), small eyes, or protruding eyes (naturally or pathologically initiated) alter the muscle length-tension relationships, thus making results less predictable. It has long been held that the eyes of adults with myopia and esotropia are difficult to align. Bilateral medial rectus recessions of 9 to 10 mm are often indicated in such instances because of the chronic stretched out elongated characteristic of the lateral rectus muscles, which must be balanced by a greater than usual recession of a taut medial rectus for even modest amounts of esotropia. Alternatively, in this case, bilateral recess-resect procedures (of lesser amounts on each muscle) are indicated to correct the modest amount of esotropia. Adjustable sutures have allowed the additional boldness necessary to find the correct balance relationship, and have revealed many interesting facets of passive mechanical and active innervational forces in a variety of unusual circumstances.

An overshooting rectus muscle, by virtue of additional innervation expressed in Hering's law induced by fixation-duress in the fixing eye, often is a difficult condition to correct satisfactorily. Greater recession of the overshooting muscle is necessary, and the additional surgical boldness indicated in such circumstances is allowable because of the safety valve of postoperative adjustment.

Adjustable procedures are well known to eyelid surgeons. Adjustable levator muscle resections are becoming increasingly popular. One must always observe the conditions necessary for full patient alertness, and absence of any infiltrative anesthesia into the muscle, *per se*. We have reported on an adjustable modified Hummelsheim transposition procedure.⁸ A postoperative adjustable upper eyelid sling blepharoptosis procedure has been described.⁹

An adjustable cyclotorsion-correcting procedure, by anteriorization and advancement of the anterior portion of the superior oblique muscle, has been devised (H. Metz, verbal communication, October 1978).¹

A question often arises as to which muscle needs an adjustable suture in cases of difficult reoperation. One should usually select the stiffer muscle (less range of normal force) since this is the muscle most likely to cause unpredictable results. This is usually the muscle that has been previously recessed a considerable degree. Perhaps it has been operated on more than once and allowed to undergo a contracture by virtue of its recessed position. Its normal range of elasticity may have diminished such that a few millimeters of advancement induce a relative leash, and a few millimeters of recession induce complete flabby slackness. In this instance, each millimeter of repositioning is of paramount importance. This is especially true if the repositioning is done with the muscle attach-

ment far posteriorly, where the lever arm is poorer and varies considerably with each increment of globe rotation. Great care must be used in advancing such a tight, shortened, and relatively inelastic muscle, and careful consideration should be given as to whether any additional resection should be combined with any advancement.^{6,7}

SUMMARY

Adjustable strabismus surgical procedures provide the opportunity to reposition a surgically altered muscle position, which is often necessary for nonaverage cases of strabismus correction. The usual surgical procedure is extended into the postoperative period (same hospitalization) so that the surgeon may satisfactorily monitor the total end result (by cover test and rotations) at the time of adjustment. Adjustable techniques should be considered whenever a desired goal is unlikely to be reached in one surgical session. Recent technical improvements allow satisfactory globe position control during the adjustment stage for ease of recession or resection adjustment. Globe stabilization is attained during surgery and the postoperative adjustment

by means of a scleral loop handle, placed near the corneoscleral limbus. Millimeters of adjustment are easily estimated by means of a sliding suture knot technique.

REFERENCES

1. Thorson, J. C., Jampolsky, A., and Scott, A. B.: Topical anesthesia for strabismus surgery. *Trans. Am. Acad. Ophthalmol. Otolaryngol.* 70:968, 1966.
2. Jampolsky, A.: Adjustable strabismus surgical techniques. Presented at the IV Congress of Conselho Latino-Americano de Estrabismo, Mexico City, May 11-16, 1974.
3. ———: Strabismus reoperation techniques. *Trans. Am. Acad. Ophthalmol. Otolaryngol.* 79:704, 1975.
4. ———: Management of acquired (adult) muscle palsies. In *Symposium on Neuroophthalmology*. St. Louis, C.V. Mosby Co., 1976, pp. 148-167.
5. ———: Adjustable strabismus surgical procedures. In *Strabismus, Symposium of the New Orleans Academy of Ophthalmology*. St. Louis, C. V. Mosby Co., 1978, chap. 24.
6. ———: Surgical leashes and reverse leashes in strabismus management. In *Strabismus, Symposium of the New Orleans Academy of Ophthalmology*. St. Louis, C. V. Mosby Co., 1978, p. 259.
7. ———: Spring-back balance test. In *Strabismus, Symposium of the New Orleans Academy of Ophthalmology*. St. Louis, C. V. Mosby Co., 1978, chap. 7.
8. Carlson, M., and Jampolsky, A.: An adjustable transposition procedure for abduction deficiencies. *Am. J. Ophthalmol.* 87:382, 1979.
9. ———: Adjustable eyelid-brow suspension. *Am. J. Ophthalmol.* 88:109, 1979.